

Dental Plexopathy

Vesta Guzeviciene, Ricardas Kubilius, Gintautas Sabalys

SUMMARY

Aim and purpose of the study were: 1) to study and compare unfavorable factors playing role in the development of upper teeth plexitis and upper teeth plexopathy; 2) to study peculiarities of clinical manifestation of upper teeth plexitis and upper teeth plexopathy, and to establish their diagnostic value; 3) to optimize the treatment.

The results of examination and treatment of 79 patients with upper teeth plexitis (UTP-is) and 63 patients with upper teeth plexopathy (UTP-ty) are described in the article. Questions of the etiology, pathogenesis and differential diagnosis are discussed, methods of complex medicamental and surgical treatment are presented.

Keywords: atypical facial neuralgia, atypical odontalgia, atypical facial pain, vascular toothache.

PREFACE

Usually the injury of the trigeminal nerve is related to the pathology of the teeth neural plexuses. According to the literature data, injury of the upper teeth neural plexuses makes more than 7% of all neurostomatologic diseases. Many terms are used in literature to characterize the clinical symptoms complex of the above-mentioned pathology. Some authors (1, 2, 3) named it dental plexalgia or dental plexitis. Other authors (4, 5, 6, 7) suggested the term of atypical odontalgia, atypical teeth or facial pain (8, 9, 10), migraine neuralgia (11), atypical facial neuralgia (12), vascular teeth pain (13), phantom teeth pain (14, 15).

According to V. Gretchko (1), the upper teeth neural plexuses are affected more frequently. It can be explained by the fact that inferior teeth neural plexuses are missing in 50 of population.

The main symptom of the injury of the upper teeth neural plexuses is acute or chronic facial pain. Referring to the clinical manifestation and effect of the treatment, we named the acute facial pain syndrome following the injury of the upper teeth neural plexuses for the upper teeth plexitis and chronic one – the upper teeth plexopathy.

MATERIAL AND METHODS

Seventy nine patients (56 females or 70,9% and 23 males or 29,1%) and 63 patients (44 females or 69.8% and 19 males or 30.2%) suffering from the upper teeth plexitis and the upper teeth plexopathy were examined and treated in the Clinic of Facial-Maxillary Surgery and Surgical Dentistry of Kaunas Medical University.

Vesta Guzeviciene - D.D.S., PhD, Department of Oral and Maxillofacial Surgery, Kaunas Medical University, Lithuania.

Ricardas Kubilius – D.D.S., PhD, Hab. Dr., professor and Head of Department of Oral and Maxillofacial Surgery, Kaunas Medical University, Lithuania.

Gintautas Sabalys - M.D., PhD, Hab. Dr., professor of Department of Oral and Maxillofacial Surgery, Kaunas Medical University, Lithuania.

Address correspondence to Dr. V.Guzeviciene: Dept.of Oral and Maxillofacial Surgery, 2 Eiveniu str., Kaunas, Lithuania.

Besides the common clinical tests, in order to analyze in detail the etiology and pathogenesis of the aforementioned disease, its clinical manifestation and peculiarities, we performed specific examinations such as orthopantomography of the infraorbital canals, measured the velocity of blood flow in the infraorbital blood vessels (doplerography), examined the pain threshold of facial skin and oral mucous membrane in acute period and remission, and evaluated the role that the state of maxillary sinus plays in the development of the upper teeth plexitis and plexopathy.

RESULTS AND DISCUSSION

Females made more than 70% of the examined patients suffering from the upper teeth plexopathy (Fig. 1). It correlates with the M.N. Puzin's data (2) who stated that great majority (about 85%) of the patients suffering from the injury of the upper teeth neural plexuses are females.

A. Wooda and P. Pionchon (16) more frequent injury of the upper teeth neural plexuses among the females associate with postmenopausal hormonal disbalance.

It is worth to note that there were more elder patients among the patients with upper teeth plexopathy than with upper teeth plexitis. The mean age was 55.6 and 51.2 years respectively (Fig. 2).

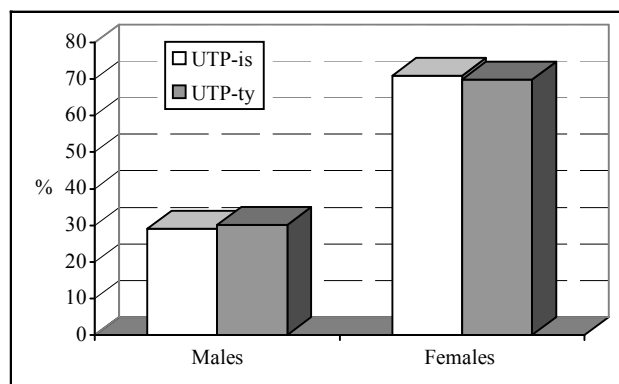


Figure 1. Distribution of the patients according to gender.

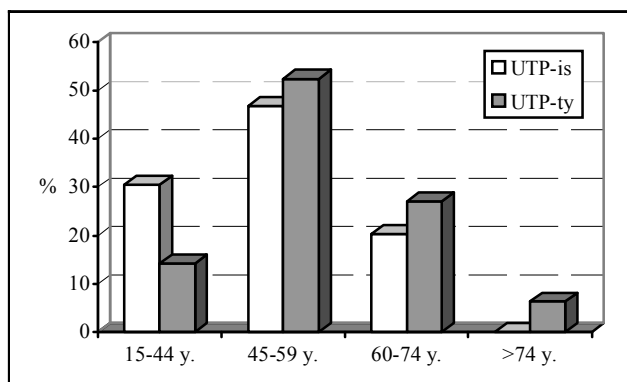


Figure 2. Distribution of patients according to age.

The duration of the upper teeth plexitis did not exceed 3 years almost in all cases (94.9%). The duration of the upper teeth plexopathy was longer than 3 years in 84.1% of cases (Fig. 3).

Main factors in the development of the upper teeth plexitis and plexopathy were following: pathologic conditions of teeth and periodontal tissues and inflammation of the maxillary sinus (Table 1).

It is worth to note that various traumatic manipulations in the teeth and maxillary region such as operations because of osteomyelitis, cysts and tumors, excessive seal pushing through the root of the tooth, operative extraction of impacted teeth (17), extraction of a large number of teeth during the same procedure play a great role in anamnesis of patients with upper teeth plexopathy and plexitis. It gives the reason to suppose that aforementioned local maxillary and teeth factors can be the direct cause of the development of these diseases.

Such our opinion corresponds to one of many authors supposing that odontogenic factors and pathological conditions of the ENT organs play the main role in the development of injury of the upper teeth neural plexuses (18, 2).

M.N. Puzin and M.N. Sharoff (19) point out that pushing the excessive amount of sealing into the periodontium causes some "strange" and "unpleasant" sensations of "heaviness" or "pressure" in the region of the sealed tooth. These sensations can last for months, decrease in intensity and cease, or become the chronic syndrome of dull pain, common for the upper teeth plexitis. General infectious inflammatory elements such as adenoviral infection and flu are supposed to play a considerable role in the development of upper teeth plexitis.

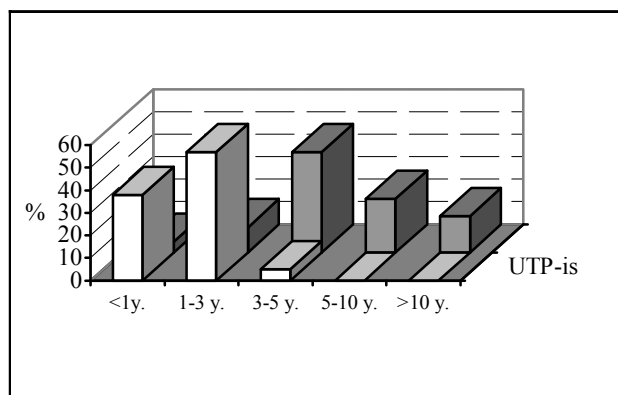


Figure 3. Distribution of patients according to the duration of the disease.

Many tumors can also play role in the development of dental plexitis. Many authors (12, 4, 6) specify that vascular factors, changes in the organism due to ageing, various traumatic injuries of peripheral vegetative neural structures play a significant role in the pathogenesis of upper teeth plexitis. Psychogenic factors such as depression also play a significant role in the etiology of this disease (22, 23).

R. Moulton (24) states that persisting pain in case of dental plexitis is the symptom of uncured depression. Also depression itself in such cases is "atypical" and does not have its common symptoms.

Predisposing factors for the development of upper teeth plexitis and plexopathy are the following: spastic dysfunction of the temporomandibular joint, cervical osteochondrosis, hyperergic reactions and dysfunction of autonomous nervous system, and disorders of vasomotorial function (8, 25).

Atherosclerosis and hypertension dominated among other general pathologic conditions of the patients we examined. They were diagnosed in more than 50% of patients with upper teeth plexitis and plexopathy as well. Atherosclerosis and hypertension can not be direct causes of the analyzed prosopalgias, but play the corresponding role in their pathogenesis.

Important fact is that upper teeth plexopathy in 81.3% of cases developed following upper teeth plexitis. That fact means these prosopalgias to have the same genesis, or, to be more precise, they are different stages of the same pathologic process. Inflammatory processes dominate in cases of upper teeth plexitis and upper teeth plexalgia manifests after the structural, i.e. destructive changes have developed.

The results of our examinations of sensory function prove that statement. Hyperesthesia of the mucous membrane of the maxillary alveolar process on

Table 1. Pathological conditions and unfavorable factors among the patients examined.

Pathological conditions and unfavorable factors	UTP-is patients		UTP-ty patients	
	n	%	n	%
Following the upper teeth plexitis (UTP-is)	-	-	52	81.3
Pathologic conditions of teeth and periodontal tissues	68	86.1	63	100.0
Inflammation of the maxillary sinus	39	49.4	32	50.8
Maxillary operations because of osteomyelitis, cysts, tumors	13	16.5	12	19.0
Excessive seal pushing through the root of the tooth	11	13.9	9	14.3
Maxillary fractures	7	8.9	4	6.3
Operative extraction of the impacted teeth	7	8.9	8	12.7
Extraction of a large number of teeth during the same procedure	6	7.6	4	6.3
Infectious diseases	2	2.5	1	1.6

Table 2. Results of the pain threshold measurements.

Group examined	Before the treatment		Asymmetry coefficient	After the treatment		Asymmetry coefficient
	Pain threshold μ A			Pain threshold μ A		
	Contra-lateral side	Affected side		Contra-lateral side	Affected side	
Control group	28,71 \pm 4,19 ^L	28,42 \pm 4,01 ^R	1,01	-	-	-
UTP-is patients	28,59 \pm 3,75	19,42 \pm 3,79*	1,47*	28,63 \pm 3,87	25,55 \pm 4,22	1,12
UTP-ty patients	27,63 \pm 3,22	74,25 \pm 4,11*	0,37*	28,41 \pm 3,17	72,25 \pm 4,12*	0,39*

L – left side, R – right side.

* – the difference is statistically significant, comparing with the control group ($p < 0,05$).

the affected side was found in patients with upper teeth plexitis. Pain threshold was statistically significantly lower comparing with the contra-lateral side and control group (Table 2).

We found hypesthesia and significantly higher pain thresholds of the maxillary alveolar process on the affected side in patients with upper teeth plexopathy.

Pain thresholds of the mucous membrane of the maxillary alveolar process on the affected side became equivalent to the ones on the contra-lateral side after the treatment during the remission period (differences were statistically insignificant).

Pain thresholds on the affected side remained practically unchanged after the treatment in patients with upper teeth plexopathy. They remained much higher than on contra-lateral side.

The symptom of neural function “disappearance” remaining after the treatment shows that irreversible destructive changes took place in dental neural plexuses.

The character and duration of pain, the main symptom of these diseases, is different. Some authors (26, 5, 23, 21) state that pain localizes in the area of endodontically treated teeth, gums or alveolar process. Other authors (4, 27) point out that pain can be the only symptom of depressive or monosymptomatic hypochondriac psychosis related to emotional status, anxiety or stress.

R.Nicolodi and F. Sicuteri (22) state that there is a greater probability of developing injury of dental neural plexuses if the anatomic structure or area (tooth, gums, alveolar process) was already painful before the therapeutic or surgical intervention or the intervention itself was painful.

In cases of upper teeth plexitis pain localizes in maxillary alveolar process, gums or in the area of certain teeth, it is sharp, stabbing, paroxysmal or constant with periods of intensification lasting from few minutes till a quarter of an hour, rarely irradiating to other facial or jaw areas.

Pain localization is the same in cases of upper teeth plexopathy, but it is constant, dull, gnawing, burning or breaching. Pain is missing in some cases, but patients feel paresthesias in the aforementioned pain localization areas (7).

Some diagnostic peculiarities are common for both upper teeth plexitis and plexopathy: pain does not

diminish after local anesthetic block, it diminishes or ceases while eating, chewing, it intensifies after catching cold, getting nervous or following the endodontic procedures. Many patients point out that one or several certain teeth are aching which are usually intact or affected only by superficial caries. Following the requirements of patients, pulpectomies of such intact or affected only by superficial caries teeth or teeth extractions were performed if the pain persisted. Later, the same patients appealed to dentists for extraction of adjacent teeth. Sometimes, when patients insisted, such teeth were extracted as well.

The treatment tactic of injury of upper teeth neural plexuses depends on the condition of maxillary sinus and the character of pain syndrome. Under the indications for treatment with medicaments, maxillary sinus was cured following the method proposed and introduced in our clinic, i.e. through the artificial fistula of the maxillary sinus. Under the indications for surgical treatment the radical operation of maxillary sinus was performed in a routine way.

Non-steroid anti-inflammatory agents, glucocorticoids, antihistaminic preparations, vasodilators, calcium preparations, ascorbic acid, anticonvulsants of Carbamazepine or Aethosuximidum group were used for the treatment of pain syndrome of upper teeth plexitis.

Complex for treatment with medicaments of upper teeth plexopathy consisted of non-steroid anti-inflammatory agents, analgesics, antihistaminic preparations, vasodilators, preparations of vitamin B group and intraosseous injections of Kenolog into dental plexuses according to the method proposed by us.

CONCLUSIONS

1. Pathologic conditions of teeth and periodontal tissue, maxillary sinus and various traumatic manipulations in the dental and maxillary regions are the main factors, which can play the critical role in the development of upper teeth plexitis and plexopathy.

2. The evaluation of pain character and duration, disturbances of sensation and determination of mucous membrane pain thresholds of the maxillary alveolar process are of crucial value in the differential diagnosis of upper teeth plexitis and plexopathy.

3. Treatment plan of the dental plexuses injury is determined with the respect to the maxillary sinus state and the character of pain syndrome.

REFERENCES

1. Гречко ВЕ. Неотложная помощь в нейростоматологии. Москва; 1981. с. 200-5.
2. Пузин МН. Нейростоматологические заболевания. Москва; 1997.
3. Синева НА, Ирошников ЕС. Изменение чувствительности слизистой оболочки полости рта при двусторонних синдромах поражения системы тройничного нерва. *Стоматология* 1979; 3: 23-7.
4. Bates RE, Stewart CM. Atypical odontalgia: Phantom tooth pain. *Oral Surg Oral Med Oral Pathol* 1991; 72: 479-83.
5. Graff-Radford SB, Solberg WK. Atypical odontalgia. *J Craniomandib Disord* 1992; 6: 260-5.
6. Schnurr RF, Brooke RJ. Atypical odontalgia: Update and comment on long-term follow-up. *Oral Surg. Oral Med. Oral Pathol* 1992; 73: 445-8.
7. Türp JC. Atypical odontalgia – a little known phantom pain. *Scherz* 2001;15(1):59-64.
8. Ziccardi VB, Janasky JE, Patterson GT, Jannetta PJ. Peripheral trigeminal nerve surgery for patients with atypical facial pain. *J Craniomaxillofac Surg* 1994; 22: 355-60.
9. Harrison SD, Balawi SA, Feinmann C, et al. Atypical facial pain: a double blind placebo controlled crossover pilot study of subcutaneous sumatriptan. *Eur Neuropsychopharmacol* 1997; 7: 83-8.
10. Jaaskelainen SK, Forssell H, Tenovuo O. Electrophysiological testing of trigeminofacial system: aid in the diagnosis of atypical facial pain. *Pain* 1999; 80: 191-200.
11. Brooke RJ. Periodic migrainous neuralgia: A cause of dental pain. *Oral Med* 1978; 46: 511-6.
12. Marbach JJ, Hulbrock J, Hohn C, Segal AG. Incidence of phantom tooth pain: An atypical facial neuralgia. *Oral Surg Oral Med Oral Pathol* 1982; 53:190-3.
13. Bell WH. Orofacial Pains: Classification, Diagnosis, Management. 3rd ed. Chicago;1985.
14. Sicuteri F, Nicolodi M, Fusco BM, Orlando S. Idiopathic headache as a possible risk factor for phantom tooth pain. *Headache* 1991; 31: 577-81.
15. Batttrum DE, Gutmann JL. Phantom tooth pain: a diagnosis of exclusion. *Int Endod J* 1996; 29: 190-4.
16. Woda A, Pionchon P. Orofacial idiopathic pain: clinical signs, causes and mechanisms. *Rev. Neurol. (Paris)* 2001; 157: 265-83.
17. Berge TI. Incidence of chronic neuropathic pain subsequent to surgical removal of impacted third molars. *Acta Odontol Scand.* 2002; 60:108-12.
18. Acquadro MA, Montgomery WW. Treatment of chronic paranasal sinus pain with minimal sinus disease (see comments). *Ann Otol Rhinol Laryngol.* 1996; 105: 607-14.
19. Пузин МН, Шаров НМ. Дентальная плексалгия (невралгия зубных сплетений). Москва, 1990.
20. Marbach JJ. Phantom tooth pain: differential diagnosis and treatment. *N Y State Dent J* 1993;59(10):28-33.
21. Vickers ER, Cousins MJ, Walker S, Chisholm K. Analysis of 50 patients with atypical odontalgia. A preliminary report on pharmacological procedures for diagnosis and treatment. *Oral Surg Oral Med Oral Pathol Oral Radiol Endod* 1998 ;85(1):24-32.
22. Nicolodi M, Sicuteri F. Phantom tooth pain diagnosis and an anamnestic focus on headache. *N Y State Dent J* 1993; 59: 35-37.
23. Friedman MH. Atypical facial pain: the consistency of ipsilateral maxillary area tenderness and elevated temperature. *J Am Dent Assoc* 1995; 126: 855-60.
24. Moulton RE. Psychiatric considerations in maxillofacial pain. *JADA* 1955; 51: 408-14.
25. Marbach JJ. Medically unexplained chronic orofacial pain. Temporomandibular pain and dysfunction syndrome, orofacial phantom pain, burning mouth syndrome and trigeminal neuralgia. *Med Clin North Amer* 1999; 83: 691-710.
26. Brooke RJ, Schnurr RF. Atypical odontalgia. Its aetiology and prognosis. *N Y State Dent J* 1993; 59: 46-9.
27. Van der Bijl P. Psychogenic pain in dentistry. *Compendium* 1995; 16.46; 48; 50-53; quiz 54.

Received: 22 04 2003
Accepted for publishing: 27 06 2003