

An Atraumatic Technique for Fabricating Precise Impressions

Antanas Cernikis, Zygintas Jonaitis, Aleksandras Loginovas

The fabrication of a dental impression that is accurate and free of voids, surface defects, and other imperfections is a challenging task, especially when extensive restorative work is being performed. Often several impressions must be taken, when doctor sets one's sight on defect free impression, that precisely replicates all details of preparation. Repetition is a tiresome process that wastes material and can tax the tolerance of both doctor and patient. The numerous attempts of scientists and practitioners to improve impression materials and the techniques for applying them testify to the difficulties inherent in this procedure^{1,2,3,4}

Of particular importance is the need to avoid damaging the gingival sulcus and junctional epithelium in the course of tooth preparation, gingival retraction, and impression-taking. The potential for insulting the periodontium is particularly great when a complete-coverage crown restoration is performed.

An examination of the histological components of the periodontium shows, that the alveolar crest is covered by the supracrestal fiber complex (Sharpey's fibers), the junctional epithelium, and the gingival sulcus. The sulcus is very limited in depth - less than 1mm in a healthy periodontium. The sulcular epithelium is non-keratinized. The dentogingival junction (biologic width) seals the underlying connective tissue of the periodontium from the oral environment⁵.

Iatrogenic disruption of the junctional epithelium may cause an inflammatory lesion in the gingival corium and fiber apparatus. This can lead to gingival recession, migration of the junctional epithelium, and permanent bone loss⁷.

If retraction cords are tightly packed for a prolonged period (i.e. more than five minutes), the cords may harm the attachment apparatus. Retraction of inflamed gingivae may result in a permanent loss of attachment⁶. In other cases,

when the gingival sulcus is damaged by perodontitis or a faulty restoration, the application of a retraction cord may be impossible (Figure 19).

In summation, any impression technique must respect the fragility of the junctional epithelium and the attachment of the supracrestal fibers and take care not to disrupt them⁸.

The following technique makes the fabrication of a high-quality impression possible, without gingival retraction, on the very first attempt.

The teeth are prepared for a prosthesis (Figure 1) A preliminary impression is taken without performing gingival retraction, using the simultaneous putty/wash technique with vinyl polysiloxane impression material (Figures 2 and 3).

A thin-wall segment of this preliminary impression is cut out with a scalpel (Figures 4 and 5). The segment is further thinned until the wall thickness is 2-3 millimeters and discontinuity with the gingiva is achieved (Figure 6). Additional interdental cuts are made to increase the flexibility of the segment. Longitudinal cuts are also made to allow for the escape of excess wash material (Figure 7).

After making sure that the segment is completely dry, it is then tried in on the prepared teeth, making sure that it fits well and overlaps the teeth without any hindrance (Figure 8). Next, the segment is filled with low-viscosity impression material (Figure 9), and the same material is syringed onto the prepared teeth (Figure 10).

The segment is then placed on the prepared teeth (Figure 11). A custom tray is loaded with putty and medium-viscosity material (Figure 12) and seated in the mouth over the segment covering the prepared teeth (Figure 13). After the impression material sets, the tray is removed and carefully examined through a magnifying lens.

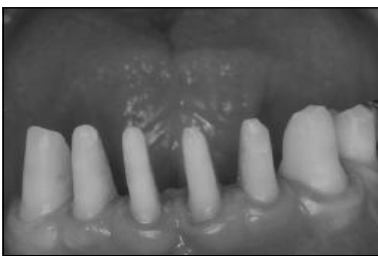

Figure 1. Teeth of the lower jaw are prepared for the PFM prosthesis.

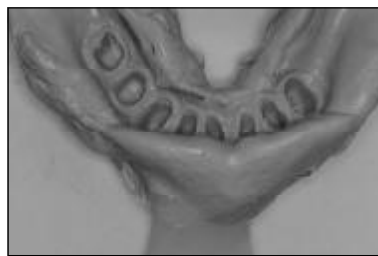

Figure 2. The preliminary impression is taken without performing gingival retraction.

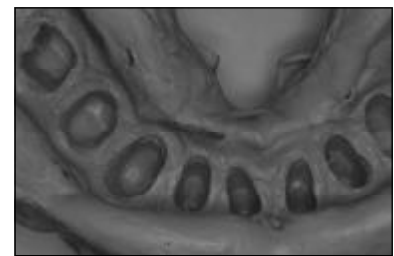


Figure 3. The preliminary impression is taken without performing gingival retraction.

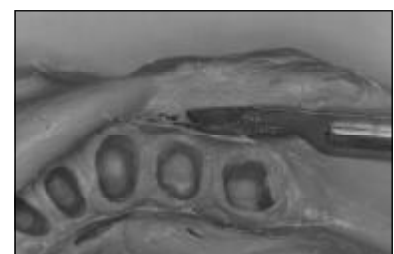


Figure 4. A scalpel is used to excise a segment of the preliminary impression.

Antanas Cernikis, D.D.S., PhD, Odontologic Clinic, private practice, Kaunas, Lithuania.

Zygintas Jonaitis, D.D.S., Odontologic Clinic, private practice, Kaunas, Lithuania.

Aleksandras Loginovas, Dr.Eng., Assoc. Prof. at Professional Training Centre, Kaunas University of Technology.

Address correspondence to: Antanas Cernikis, Odontologic Clinic, Laisves al. 72B-7, Kaunas LT-3000, Lithuania.

E-mail: birute@kalnieciai.lt

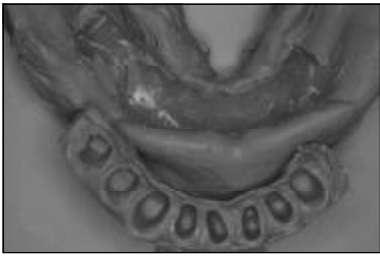

Figure 5. The excised segment.

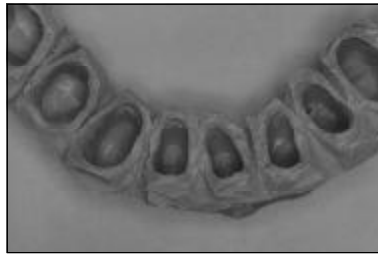

Figure 6. The prepared thin-wall segment, after reduction of the wall thickness to 2-3 mm.

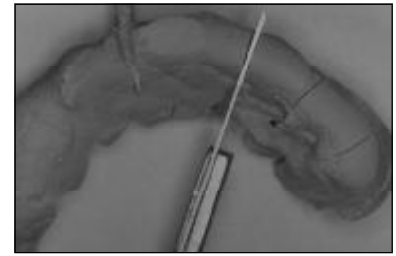


Figure 7. Longitudinal cuts allow for the outflow of the excess of low-viscosity material.

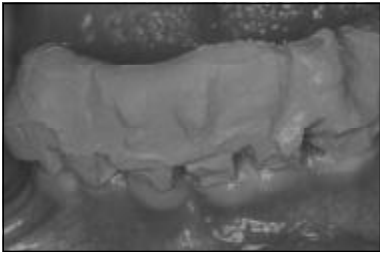


Figure 8. The completed segment is tried in on the prepared teeth.



Figure 9. The segment is filled with low-viscosity material.

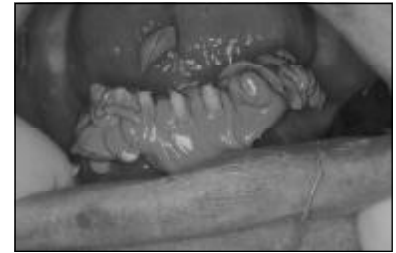

Figure 10. Low-viscosity material is also syringed on the prepared teeth.




Figure 11. The segment is placed on the prepared teeth.

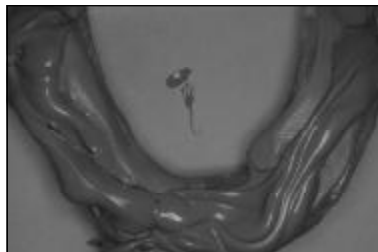

Figure 12. A custom tray is loaded with putty and medium-viscosity material.

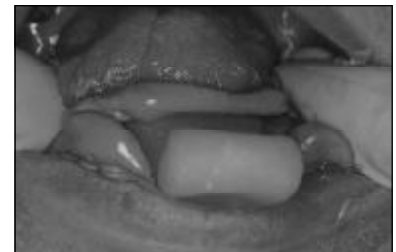


Figure 13. The custom tray is seated in the mouth over the segment covering the prepared teeth.

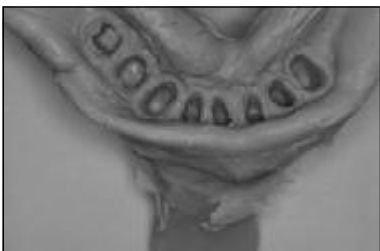

Figure 14. The final impression.

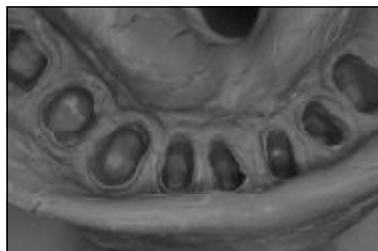

Figure 15. The final impression.

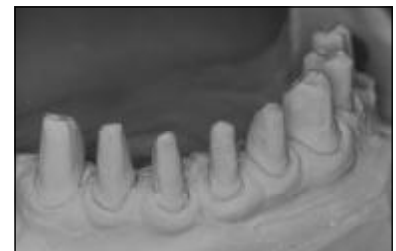

Figure 16. The cast.

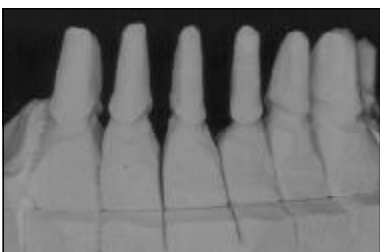

Figure 17. The trimmed cast.

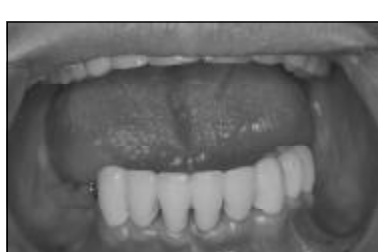

Figure 18. The completed PFM prosthesis.

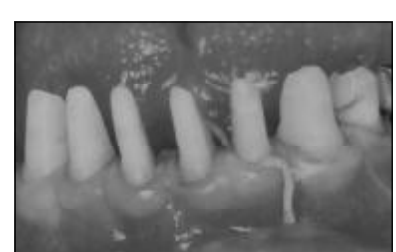


Figure 19. Gingival retraction may be impossible, due to a shallow sulcus.

The impression is considered to be of high quality and complete when all contours are clear, especially the edges of the shoulder and gingival sulcus (Figures 14 and 15). A model cast using such an impression will precisely reflect the surfaces of the prepared teeth (Figure 16 and 17).

A completed porcelain-fused-to-metal (PFM) prosthesis fabricated using this impression technique is shown in Figure 18.

The problem of air voids is common to all impression fabrication techniques. However, it is impossible to completely avoid air voids while mixing the impression materials. The bigger amount of the impression material is placed on the tray, the bigger is probability of air void defects in the impression. Majority of impression techniques require to perform gingival retraction using retraction cords or rings, which may often traumatize gingival sulcus and fiber apparatus

The essence of this technique involves excising a thin-wall segment of the prepared-teeth replica from the preliminary impression and placing the segment on the prepared teeth in the mouth. During seating of the segment over the prepared teeth, the pressure on the wash material increases. It increases further during seating of the custom tray filled with putty material over the thin-wall segment. The very thin layer of the elastic wash material flows under pressure into the gingival sulcus, and its excess flows out through longitudinal cuts and margins of the fragment, displacing humidity and air voids and precisely replicating the preparation. The volume of this very thin layer of wash material is very little, so the influence of the polymerisation shrinkage on dimensional accuracy of final impression is significantly reduced. In addition an accuracy is greatly improved by first taking preliminary impression with a highly filled putty, and after setting, cutting out the segment and taking a sec-

ond impression with a light bodied wash material. Thus the final total shrinkage is lower.⁹

The authors have been using the above-described impression technique since 1997 for crown, bridge, telescopic copings, and inlay-onlay restorations. Gingival retraction was avoided in all these cases. The consumption of impression materials also was reduced, along with patient treatment time and the concomitant wear and tear, physical and emotional, on both patients and dentists. Use of this technique has furthermore improved the quality of the prostheses. Authors may state, on the basis of the preliminary (still ongoing) laboratory tests, that this technique, in cooperation with a highly skilled technician, allows to achieve marginal integrity of the final prostheses in the scale of 40-50µm. Implementation of this technique in the daily practice improved communication with laboratory technicians, to the benefit of the overall working relationship. Misunderstandings have been avoided due to the high-quality prostheses fabricated as a result of applying this impression technique.

CONCLUSION

1. Application of the above described technique makes it possible to fabricate high-quality defect-free impressions without gingival retraction.

2. Refusal of the gingival retraction excludes the possibility to damage gingival sulcus, junctional epithelium and underlying fiber complex (biologic width).

3. Defects, pulls, air voids in the impression are excluded due to high dynamic pressure in the wash material, in the small space between prepared tooth and the inner wall of the segment.

4. The final total shrinkage of the impression is reduced, due to reduction of the volume of setting materials.

REFERENCES

1. Millar BJ, Dunne SM, Robinson PB. An in vivo study of a clinical surfactant used with poly (vinylsiloxane) impression materials. *Quintessence Int* 1996; 27:707-9.
2. Chai J, Takahashi Y, Lautenschlager EP. Clinically relevant mechanical properties of elastomeric impression materials. *Prosthodontics* 1998; 11: 219-23.
3. Werrin SR. The two-minute impression technique. *Quintessence Int* 1996; 27: 179-81.
4. O'Brien WJ. Impression materials. In: Dental materials and their selection. Chicago: Quintessence Publ Co Inc; 1997. p. 123-146.
5. Berkowitz BKB, Holland GR, Maxham BJ. Colour atlas and text-book of oral anatomy. Wolfe Med Publ Ltd ;1978. p. 129-32.
6. Wise MD. Tooth preparation, gingival retraction, hydrocolloid technique, master cast systems, soldering. In: Failure in the restored dentition: management and treatment. London: Quintessence Publ Co Ltd; 1995. p. 189-90.
7. Wilson RD. Restorative dentistry. In: Wilson TG, Kornman KS, Newman MG, editors. Advances in periodontics. Chicago: Quintessence Publ Co Inc; 1992. p. 226-30.
8. Nevins M, Cappetta EG. The biologic width: preventing post-surgical recession. In: Nevins M, Mellonig, editors. Periodontal therapy, clinical approaches, and evidence of success. Vol 1. Chicago: Quintessence Publ Co Inc; 1998. p. 305-7.
9. O'Brien WJ. Impression materials. In: Dental materials and their selection. Chicago: Quintessence Publ Co Inc; 1997. p. 134-5.

Received: 2003 11 22

Accepted for publishing: 2003 11 27