

Accuracy of Traditional Clinical Examination in Combination with 3-D Computerized Axiography for Diagnosing Anterior Disk Displacement with Reduction

Giedre Kobs, Olaf Bernhardt, Thomas Kocher, Georg Meyer

SUMMARY

Statement of problem. Magnetic resonance imaging (MRI) was reported to be a non-invasive and useful tool for diagnosing disk displacement. However, cost and availability often limit the use of MRI. The clinician must often rely on the patients history and clinical examination findings to establish the diagnosis.

Purpose. The objective of this study was to evaluate the diagnostic accuracy of a clinical examination in combination with computerized axiography for diagnosing anterior disk displacement with reduction.

Material and methods. 464 joints with no disk displacement (NDD), 114 joints with reducible displaced disk (RDD), and 36 joints with permanently displaced disk (PDD) confirmed on magnetic resonance imaging (MRI) were examined by traditional clinical approach and 3-D computerized axiography.

Results. Pathological TMJ states such as RDD could be separated from healthy joints with an clinical examination sensitivity of approximately 52,8% on the right side and 59,0% on the left side. The overall accuracy for the Clicking test combined with 3-D computerized axiography was about 77,8% on the right side and 72,1% on the left side.

Conclusion. Our results suggest that anterior disk displacement with reduction can't be diagnosed with considerable accuracy though the use of a clinical examination only.

Although the predictability of identifying anterior disk displacement with reduction by clicking was relatively low, it increased to an acceptable level when additional 3-D computerized axiography were used. Within the limitation of this study we suggest, that clinical examination in combination with jaw-tracking devices is an accurate evaluation method for determination of TMJ dysfunction.

Key words: temporomandibular disorders; temporomandibular joint dysfunction; internal derangement; clinical examination; computerized axiography; magnetic resonance imaging; sensitivity; specificity

INTRODUCTION

Temporomandibular disorders (TMD) is a collective term embracing a number of clinical problems that involve the masticatory musculature, temporomandibular joint (TMJ), or both [1]. Findings from epidemiologic and experimental intervention studies indicate that TMD is a chronic pain condition that shares the major characteristics of other common chronic pain conditions, notably headache and back pain [2-3]. Therefore, to provide more tissue-specific and more effective treatment modalities for TMD patients, it is important to rule out musculoskeletal conditions similar to TMD and to subclassify individual patients into specific TMD subgroups on the basis of precise diagnoses [4]. MR imaging has become the gold standard for evaluating the soft tissue structures of the TMD, especially disk position [5], and it has the major advantage of not introducing radia-

tion or known biologic hazards to the patient that might produce tissue damage [6]. However, MR imaging units are quite expensive and not available in a traditional dental setting. The clinician must often rely on the patients history and clinical examination findings. Axiographic recordings of the mandibular joint motion permit the diagnosis of muscular dyscoordination, hyper- and hypomobility, dynamic asymmetries of movement, avoidance mechanisms, and joint pathologies [7-8] and therewith improve the accuracy of clinical diagnosis [9]. However, the literature does not suggest that the sensitivity and specificity of jaw-tracking devices are reliable enough to be used for diagnosis and management of TMDs [6, 10-11].

In this study we evaluated the diagnostic accuracy of traditional clinical examination alone and in combination with 3-D computerized axiography for diagnosing anterior disk displacement with reduction, because it is the major form of TMJ internal derangements among the TMD population.

MATERIALS AND METHODS

Subjects

From a population representative cross-sectional study - "Study of Health in Pomerania" (SHIP) there were 307 subjects (140 males und 167 females) selected for this investigation. The age of subjects ranged from 20 to 54 years old, with a mean age of 35, 4.

Due to the clinical diagnosis of „SHIP“ 114 subjects had at least one sign of temporomandibular disorders (tenderness/pain on palpation of the joints or muscles, TMJ

Giedre Kobs - D.D.S., PhD., Institute of Odontology, Faculty of Medicine, Vilnius University, Lithuania.

Olaf Bernhardt - D.D.S., PhD., assist. Professor, Assistant medical director at the Department of Restorative Dentistry, Periodontology and Pediatric Dentistry, University of Greifswald, Germany.

Thomas Kocher - D.D.S., PhD., Hab. Dr., Professor and Head of the Department of Periodontology, University of Greifswald, Germany.

Georg Meyer - D.D.S., PhD., Hab. Dr., Professor and Head of the Department of Restorative Dentistry, Periodontology and Pediatric Dentistry, University of Greifswald, Germany.

Address correspondence to G. Kobs: Department of Prosthodontics, Institute of Odontology Faculty of Medicine, Vilnius University, Zalgirio str. 117, Vilnius, Lithuania.

sounds, pain or deviation during maximum mouth opening (active/passive). 193 subjects served as controls. All subjects underwent computerized axiography and MRI after proper history taking and assessment of clinical symptoms.

The axiographic and MRI results were independently assessed by two experienced diagnosticians.

Collected data were compared by contingency tables and analysed with chi-square (χ^2) test. Better visualisation of results was done by graphics.

MRI diagnosis

MRI was performed with 1,0-tesla scanner (Magnetom Impact Expert, Siemens, Germany) using a bilateral TMJ surface coil with 7cm diameter as described by Kobs et al [9].

The physiological disk position was considered from two points of view:

the pars intermedia of the disk has to lie in the area of the shortest distance between anterior cranial outline of the condyle and Protuberantia articularis [13];

the junction line between the middle point of the condyle and the posterior margin of the disk must not be more than 10° from the 12 o'clock position [14].

Any forward dislocation of the disk constituted anterior displacement. The displaced disk was further categorized as reducible or permanently displaced disk depending on relationship with the condyle in an open-mouth position. If posterior band of disk was anterior to articular surface of condyle in maximal intercuspal position, but normal disk condylar relationship was established in maximal mouth opening position, it was classified as RDD. However, if the displaced disk remained in an anterior position relative to the condyle in an open-mouth position, it was classified as PDD.

Axiographic diagnosis

The registration of TMJ tracings was made with the conventional double face-bow Cadiax III-System (Gamma, Wien) as described by Kobs et al [9].

The examiner had no knowledge of the clinical and MRI findings.

Collected data were compared by contingency tables and analysed with chi-square (χ^2) test. Better visualisation of results was done by graphics.

RESULTS

In assessing the MRI, 464 joints were judged to have no disk displacement (NDD), 114 joints RDD, and 36 joints PDD. According to 3-D computerized axiography approach 433 joints judged to have no appreciable disease (NAD), 104 joints RDD, 21 PDD and 56 not classifiable pathological change (NCPC).

The clinical examination included tenderness on palpation and assessment of joint sounds together with history of joint symptoms. Table 1 shows the percentage frequency of clinical clicking. Opening click was most frequent (right side: 16,0%; left side: 18,6%), crepitation – ie, a crackling or grating sound of long duration was diagnosed for the right as well as for the left side only in 3,3% of the cases.

Table 2 shows the percentage frequency of two main TMD diagnostic subgroups: masticatory muscle disorders (myalgia) and Internal derangement.

Evaluation of Sensitivity and Specificity for diagnos-

Table 1. Percentage frequency of clinical clicking.

	C ri O	C ri Cl	C le O	C le Cl	C ri L	C le L
Negative	84,0% (258)	86,3% (265)	81,4% (250)	84,0% (258)	89,6% (275)	88,9% (273)
Positive	16,0% (49)	13,7% (42)	18,6% (57)	16,0% (49)	10,4% (32)	11,1% (34)

C ri/le O/Cl Clicking right/left opening-closing
C ri/le L Clicking right/left lateral movement

Table 2. Percentage frequency of clinical diagnoses.

	Myalgia right		Myalgia left		Internal derangement right		Internal derangement left	
	%	n	%	n	%	n	%	n
Negative	95,8	294	94,5	290	77,5	238	73,0	224
Positive	4,2	13	5,5	17	22,5	69	27,0	83

ing anterior disk displacement with reduction of a clinical examination alone is shown in Figure 1 and in combination with computerized axiography in Figure 2.

For the calculation of the clinical sensitivity and specificity, the clinical diagnosis "Internal derangement" was confronted with disk dislocations, diagnosed on MRT sagittal plane (Figure 2). For the right side sensitivity was 51,4% and specificity 89,4%. For the left side sensitivity was 52,6% and specificity 85,6%. The positive predictive value for the right joint was 59,7% and for the left joint 55,4%.

Although the predictability of identifying anterior disk displacement with reduction by clicking was relatively low (52,8% on the right and 59,0% on the left side), it increased to an acceptable level when additional 3-D computerized axiography were used (exclusion of PDD). For the right side sensitivity increased to 77,8% and specificity 86,9%. For the left side sensitivity was 72,1% and specificity 83,7%. The positive predictive value for the right joint was 60,5% and for the left joint 55,7%.

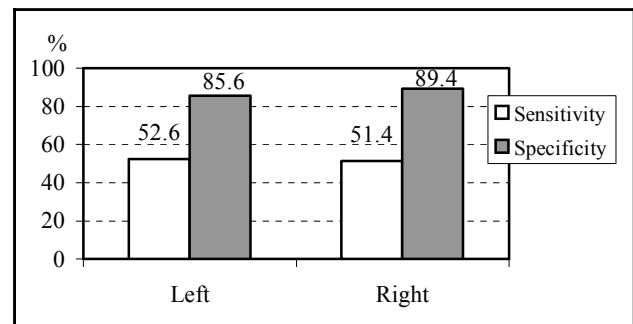


Figure 1. Sensitivity and specificity of clinical examination.

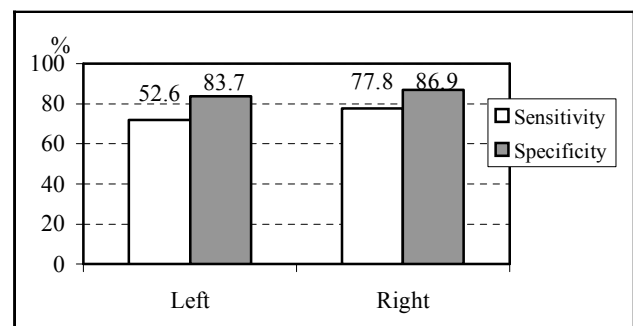


Figure 2. Diagrammed demonstration of the "clicking phenomenon" accuracy after clinical and axiographic assessment of the right and left joints.

DISCUSSION

In this investigation we attempted to establish the accuracy of traditional clinical examination alone and in combination with 3-D computerized axiography for diagnosing anterior disk displacement with reduction.

The accuracy of clinical examination for diagnosing the exact status of TMJ internal derangement has been investigated in several previous studies [15-19]. Because of the low reliability clinical examination as a gold standard in detecting morphological changes is questionable [20-23]. Even after calibration of experienced TMJ examiners, it was revealed a poor reproducibility for clinical "clicking" or "pain on palpation" of approximately 60% [24]. Due to the fact that clinical findings alone are too often non-specific as predictors of the imaging stage of disk displacement [19, 25-26], it also reduces its diagnostic value. Roberts et al. [22] and Paesani et al. [23] found a sensitivity of 43% to 78% for clinical examination compared to arthrography. Although reciprocal clicking is highly indicative for RDD and reduced translatory capacity for PDD [27]. After an MRI examination

of 90 TMJs, Stegenga et al. [28] stated that these symptoms are not pathognomonic for disk displacement. Due to its non-invasive character and its excellent visualization of soft tissues, MRI is rapidly becoming the gold standard for evaluating the soft tissue of the TMJ, especially disc position. A high sensitivity (67% -100%) of MRI for diagnosis of the correct disk position and bone changes of the TMJ was confirmed by autopsy studies [29-30]. On the other hand there was no strong relationship between TMJ symptoms and disk displacement confirmed [31]. It is questionable whether all patients with TMD-like symptoms initially require expensive MRI scans. The "clicking phenomenon" accuracy after clinical and axiographic assessment may provide the necessary data for diagnosing anterior disk displacement with reduction at a lower cost. The results suggest that anterior disk displacement with reduction can't be diagnosed with considerable accuracy though the use of a clinical examination only. The use of 3-D computerized axiography increases the accuracy of positive and differential diagnoses.

REFERENCES

- McNeill C. Introduction. In: Temporomandibular Disorders: Guidelines for Classification, Assessment, and Management. Chicago: Quintessence; 1993, p. 11-13.
- Von Korff MR, Ormel FJ, Keefe FJ, Dworkin S.F. Grading the severity of chronic pain. *Pain* 1992; 50: 133-49.
- Dworkin SF, Massoth DL. Temporomandibular disorders and chronic pain: Disease or illness? *J Prosthet Dent* 1994; 72: 29-38.
- Dworkin SF, LeResche L. Research diagnostic criteria for temporomandibular disorders: review, criteria, examinations and specifications, critique, I: review of the literature. *J Orofac Pain* 1992; 4: 307-26.
- Emshoff R, Brandlmaier I, Bertram S, Rudisch A. Comparing methods for diagnosing temporomandibular joint disc displacement without reduction. *J Am Dent Assoc* 2002; 133(4): 442-541.
- Okeson JP. Management of temporomandibular disorders and occlusion. St Luis: Mosby; 2003.
- Meyer G, dal Ri H. Dreidimensionale elektronische Messung der Bewegungen des Kondylus über die Scharnierachse des Unterkiefers. *Dtsch Zahnärztl Z* 1985; 40(8): 881-6.
- Piehslinger E, Schimmerl S, Celar A, Crowley C, Imhof H. Comparison of magnetic resonance tomography with computerized axiography in diagnosis of temporomandibular joint disorders. *J Oral Maxillofac Surg* 1995; 24(1): 13-9.
- Kobs G, Bernhardt O, Meyer G. Accuracy of computerized axiography controlled by MRI in detecting internal derangements of the TMJ. *Stomatol Baltic Dent Maxillofac J* 2004; 6 (1): 7-10.
- Mohl ND, McCall WS, Lund JP, Plesh O. Devises for the diagnosis and treatment of temporomandibular disorders: Part I. Introduction, scientific evidence, and jaw tracking. *J Prosthet Dent* 1990; 63: 198-201.
- Theusner J, Plesh O, Curtis DA, Hutton JE. Axiographic tracings of temporomandibular joint movements. *J Prosthet Dent* 1993; 69: 209-15.
- Kobs G, Bernhardt O, Meyer G. Magnetic resonance evaluation between the relationship of the temporomandibular joint disk and condylar head displacement. *Stomatol Baltic Dent and Maxillofac J* 2003; 5: 93-6.
- Bumann A, Lotzmann U. Funktionsdiagnostik und Therapieprinzipien. In: Rateitschak K.H., Wolf H.F. (Hrsg): Farbatlanten der Zahnmedizin Bd. 12. Stuttgart: Thieme-Verlag; 2000.
- Drace JE, Enzmann DR. Defining the normal temporomandibular joint: closed-, partially open-, and open-mouth MR imaging of asymptomatic subjects. *Radiology* 1990; 177(1): 67-72.
- Choligtul W, Nishiyama H, Sasai T, Uchiyama Y, Fuchihata H, Rohlin M. Clinical and magnetic resonance imaging findings in temporomandibular joint disc displacement. *Dentomaxillofac Radiol* 1997; 26(3): 183-8.
- Frahn G, John M, Thiele J. Diagnose von Diskusverlagerungen nach anterior ohne Reposition – Vergleich von klinischen und MRT-Befunden. *Stomatologie* 1997; 94(3): 133-7.
- Benito C, Casares G, Benito C. TMJ Static Disk: Correlation between clinical findings and pseudodynamic magnetic resonance images. *J Craniomand Pract* 1998; 16(4): 242-51.
- Orsini M.G, Kuboki T, Terada S, Matsuka Y, Yatani H, Yamashita A. Clinical predictability of temporomandibular joint disc displacement. *J Dent Res* 1999; 78(2): 650-60.
- Augthun M, Müller-Leisse C, Bauer W, Roth A, Spiekermann H. Anterior disk displacement of the temporomandibular joint. Significance of clinical signs and symptoms in the diagnosis. *J Orofac Orthop* 1998; 59(1): 39-46.
- Anderson GC, Schiffman EL, Schellhas KP, Friction JR. Clinical vs. arthrographic diagnosis of TMJ internal derangement. *J Dent Res* 1989; 68(5): 826-9.
- Schiffman EL, Anderson E, Friction JR, Burton K, Schellhas K. Diagnostic criteria for intraarticular T.M. disorders. *Community Dent Oral Epidemiol* 1989; 17(5): 252-7.
- Roberts CA, Katzberg RW, Tallents RH, Espeland MA, Handelman SL. The clinical predictability of internal derangements of the temporomandibular joint. *Oral Surg Oral Med Oral Pathol* 1991; 71: 412-4.
- Paesani D, Westesson PL, Hatala MP, et al. . Accuracy of clinical diagnosis for TMJ internal derangement and arthrosis. *Oral Surg Oral Med Oral Pathol* 1992; 73(3): 360-3.
- Dworkin SF, LeResche L, Von Korff MR. Assessing clinical signs of temporomandibular disorders: Reliability of clinical examiners. *J Prosthet Dent* 1994; 63: 574-9.
- Bauer W, Augthun M, Wehrbein H, et al. . Diagnostik und kieferorthopädische Relevanz der anterioren Diskusverlagerung ohne Reposition. *Fortschr Kieferorthop* 1994; 55(1): 21-7.
- Müller-Leisse C, Augthun M, Roth A, et al. Diskusvorverlagerung des Kiefergelenks: Korrelation von Magnetresonanztomographie und klinischem Untersuchungsbefund. *Fortschr Röntgenstr* 1996; 165(3): 264-9.
- Rammelsberg P, Pospiech P, May HC, Gernet W. Evaluation of diagnostic criteria from computerized axiography to detect internal derangements of the TMJ. *J Craniomand Pract* 1996b; 14(4): 286-95.
- Stengenga B, de Bont LG, van der Kuijl B, Boering G. Classification of temporomandibular joint osteoarthritis and internal derangement. I. Diagnostic significance of clinical and radiographic symptoms and signs. *Cranio* 1992; 10(2): 96-106.
- Schimmerl S, Kramer J, Stiglbauer R, et al. MRT des Kiefergelenks. *Fortschr Röntgenstr* 1993; 158(3): 192-6.
- Katzberg RW, Schenck J, Roberts D, et al. Magnetic resonance imaging of the temporomandibular joint meniscus. *Oral Surg Oral Med Oral Pathol* 1985; 59(4): 332-5.
- Westesson PL. Physical diagnosis continues to be the gold standard. *Cranio* 1999; 17(1): 3-4.

Received: 22 06 2004
Accepted for publishing: 20 09 2004