

Condylar and mandibular morphological criteria in the 2D and 3D MSCT imaging for patients with Class II division 1 subdivision malocclusion

Zane Krisjane, Ilga Urtane, Gaida Krumina, Anvita Bieza, Katrina Zepa, Irena Rogovska

SUMMARY

The condyle has a special multidirectional capacity for the growth and adaptive remodeling of temporomandibular joint (TMJ). Being part of TMJ structure, it plays an important role in the stability of long-term treatment results for orthodontic and orthognatic patients with Class II division 1 subdivision malocclusions. Several computed tomography (CT) investigation modes have been used to evaluate the craniofacial morphology and particularly, for TMJ. Dimensional images, acquired using new generation multislice CT (MSCT) and cone beam CT scanning data, are becoming increasingly popular in the clinical work and research. The aim of the study was to develop a new CT investigation protocol for the quantification of morphological structures and skeletal landmarks of condyle, *procesus condylaris* and mandible. For this purpose we created two dimensional (2D) and three dimensional (3D) reconstruction images from primary axial MSCT scans using *IAC review* and *Transparent bone* programmes and acquired accordant measurements of condylar and mandibular structures. This technic allowed to get truly volumetric reflexion of the joint components in its real anatomical size and avoided the bony superimpositions. Our material included 12 patients with skeletal Class II division 1 subdivision malocclusion who had indications for combined orthodontic and orthognatic treatment. CT examination was performed before the start of treatment. For statistical analysis paired Student t-tests were applied to test the diferences of mean values and correlation coefficients were calculated to assess possible interrelations between measurements. The preliminary results showed weak corrrelation between condylar and mandibular measurements. More significant correlation was observed between procesus condylaris and mandible. It was a significant difference between right and left side in the height of procesus condylaris in patients without clinically relevant facial asymetry which could be considered in the individual planning of orthognatic treatment.

Conclusion. The developed combined 2D and 3D MSCT investigation protocol for condylar and mandibular measurements provides precise and demonstrative quantitative images of condylar and mandibular structures and its dimensional relationships., which could be qualified as informative criteria for the individual treatment planning for patients with Class II division 1 subdivision malocclusion.

Key words: condylar morphology, Class II division 1 subdivision malocclusion, 2D and 3D MSCT.

INTRODUCTION

The condyle has a special multidirectional capacity for the growth and adaptive remodeling in

selective response to varied mandibular displacement movement and rotations. The adaptive capacity of

¹Department of Orthodontics, Institute of Stomatology, Riga Stradins University, Latvia

²Institute of Radiology, Riga Stradins University, Institute of Radiology, Latvia

Zane Krisjane¹ – postgraduate student in orthodontics

Ilga Urtane¹ – D.D.S., Dr. med., Professor and Head of Department of Orthodontics, Director of Institute of Stomatology

Gaida Krumina² – M.D., PhD., Professor, Director Institute of Radiology, Riga Stradins University

Anvita Bieza² – postgraduate student of Diagnostic Radiology

Katrina Zepa¹ – postgraduate student in orthodontics

Irena Rogovska – M.D., PhD, (University of Tampere), Medical Statistics Consultant, Institute of Stomatology, Rigas Stradins University

Address correspondence to Dr. Zane Krisjane, Department of Orthodontics, Institute of Stomatology, Riga Stradins University, 20 Dzirciema Street, Riga, Latvia, LV 1007.

E-mail: krisjane.zane@inbox.lv

condyle involves the entire ramus. The ramus is an important anatomic part directly involved in growth compensations [1].

During the growth and in response to orthodontic treatment the mandibular rami and condyle develop in many directions relative to all possible individual variations. The evidence that rami and condyles might play adaptive role in the skeletal growth and response to treatment comes from the findings of implant studies [2].

Changes in occlusion (orthodontics, orthognathic surgery) could contribute to remodeling of the articular structures of the TMJ and could be a reason for condylar resorption and changes in the mandibular structure [3, 4].

Previously morphological characteristics of temporomandibular joint and particularly condyle and mandible in association with malocclusion have been studied with various imaging modalities. Several studies have been conducted for the examination of condyle and *fossa articularis* morphology using panoramotomography and standardized lateral tomogram [5, 6, 7, 8, 9, 10]. Nevertheless, quantitative measurements of this structure on conventional radiological images are difficult because of magnification differences, topography of adjacent anatomical structures and image distortions [8, 9, 11, 12].

The diagnostic accuracy with conventional 2D radiography is limited because of difficulties in imaging of the point – the location of condyle within cranial base results in bony superimpositions and structural distortions in film techniques [13].

2D and 3D CT craniofacial imaging techniques are becoming increasingly popular and have opened new possibilities in orthodontics. New generation 3D method based on MSCT scanning have been recently introduced and have already made a distribution to dentofacial imaging [14, 15]. It's proposed that 3D imaging could be an effective method for assessment of condylar and mandibular morphology in the predicting of mandibular rotation and quantifying outcomes of orthodontic treatment and orthognathic surgery [16, 17].

Aim

The aim of our study was to develop a new MSCT investigation protocol with appropriate 2D and 3D images reconstructions and measurements algorithm, valid for the quantification of morphological structure and skeletal landmarks of the condyle, *processus condylaris* and mandible in patients with Class II division 1 subdivision malocclusion.

MATERIAL AND METHOD

Twelve patients (9 women and 3 men) with mean age 18.2 years were included in the study group. All subjects had skeletal Class II division 1 subdivision malocclusion, with overjet more than 6 mm, increased ANB angle and with indications for combined orthodontic treatment and orthognathic surgery. They had no evident facial asymmetry, no functional mandibular deviations nor rheumatoid or traumatic symptoms. Symptoms of temporomandibular disorders were not considered in selecting these subjects and they had not undergone previous orthodontic treatment. Conventional clinical and radiological examination of occlusion and TMJ was used. Before starting preorthognathic orthodontic treatment, CT investigation was performed using GE Medical Systems Light Speed Pro 16CT99_Oc0 system. All the measurements were automatized and standardized according to parameters of the equipment. The position of the patient was lying on the back, head positioned in the middle of orbitomeatal plane, closed mouth position – direct touch of molar teeth in habitual occlusion. Axial scanning was done from soft tissue point *Glabella* down to upper margin of C6. CT scan protocol – helical full 1.0 s, slice thickness 0.625 mm, pitch 0.625 mm. 2D and 3D reconstruction images – bone and soft tissue using *IAC Review* and *Transparent bone* programs on the workstation were acquired.

Following measurements were done: height of condyle – linear distance between the top of condyle and crosssectional line that goes from the most prominent point of condyle and is perpendicular to the tangent of *ramus mandibulae* (Fig. 1); length of condyle – linear distance between the anterior and posterior point of condyle in sagittal plane (Fig. 2); height of *processus condylaris* – linear distance between the highest point of condyle and line that goes through *incisura mandibulae* and is perpendicular to the tangent of *ramus mandibulae* (Fig. 3); length of mandibula – distance between the most distal point of condyle and *Gnathion* (Fig. 4); height of mandibular ramus – distance between the highest point of condyle and *Gonion* (Fig. 5); mandibular body length – distance between points *Gonion* and *Gnathion* (Fig. 6).

Study was approved by Rigas Stradins University Ethical committee.

Statistical analysis

All the measurements were done by the one operator three times. Intraobserver measurement error was 0.8. The mean value of these three measurements was used for the statistical analysis.

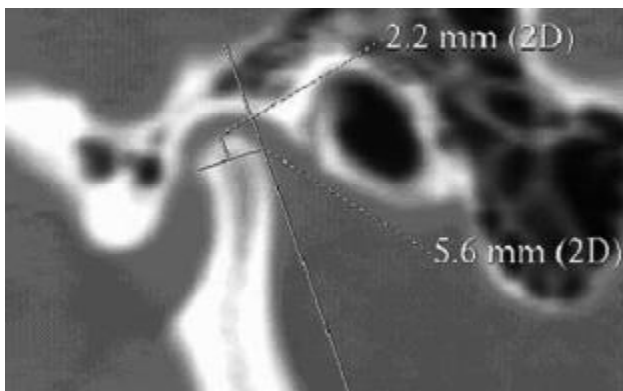


Fig. 1. 2D MSCT reconstruction image. Height of condyle




Fig. 2. 2D MSCT reconstruction image. Length of condyle




Fig. 3. 2D MSCT reconstruction image. Height of condylar process

Mean values of condylar and mandibular measurements were calculated separately for the left and right side. Differences of mean values were tested using paired t-test. Correlation coefficients were calculated to assess possible interrelation between mandibular, condylar and *processus condylaris* measurements. Mean values of measurements and correlation coefficients were calculated separately for left and right side.

RESULTS

The average values of mandibular, condylar and

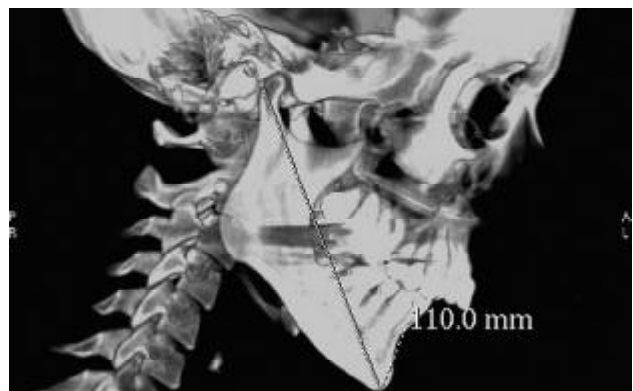

Fig. 4. 3D MSCT reconstruction image. Length of mandibulae

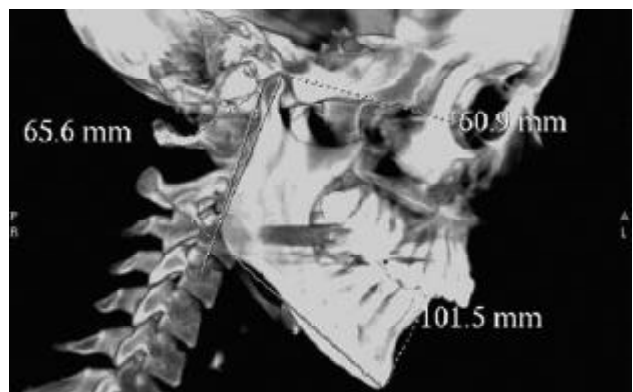


Fig. 5. 3D MSCT reconstruction image. Height of mandibular ramus

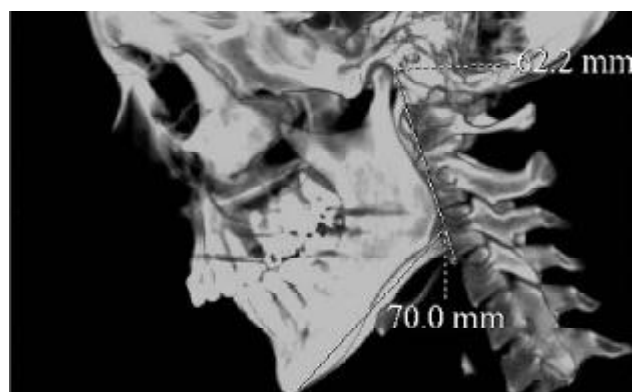


Fig. 6. 3D MSCT reconstruction image. Length of mandibular body

processus condylaris measurements are given in Table 1.

Mean values of the length of mandibulae and the height of *processus condylaris* on the right and left side were different with statistical significance (Table 1).

Association between condylar height and mandibular measurements has not been confirmed with remarkable correlations (Table 2). However, association between condylar length and mandibular measurements was characterized with mainly negative and more significant correlations (Table 2). By analysing the correlations between *processus*

condylaris height and mandibular measurements, we found strong association between all variables. On the right side there was correlation between *processus condylaris* height and the length of mandible ($r=0.85$), mandibular body length ($r=0.96$) and the height of mandibular ramus ($r=0.49$). These correlations were also established on the left side but they were very homogenous – respectively $r=0.67$; $r=0.6$; $r=0.61$ (Table 2).

DISCUSSION

The development of 3D CT digital modeling of patient's craniofacial structure greatly improve the ability to determine the true anatomical structure and to quantify precisely located and measured skeletal landmarks comparing with traditional 2D imaging [16, 18, 21] 3D MSCT avoids the superimposition of adjacent structure and allows bone details to be displaced at high resolution – it allows for a unique appreciation of the intercorrelations between structures [19, 20, 21]. Recently 3D cephalometry was developed and validated by using spiral MSCT data [19, 20].

A new generation of dentofacial imaging systems based on cone-beam CT (CBCT) scanning, was introduced and it has made contribution to dentofacial imaging [22, 23].

Swennen and Schutyser [19, 20] specify at several advantages of MS-CT 3D cephalometry that could be refer to condyle and mandible imaging : truly volumetric 3D depiction of hard and soft tissue of the skull, real-size 1:1 scale, no superimposition of anatomic structures, high accuracy and reliability. However, MSCT 3D data acquisition has some drawbacks: limited access for the routine craniofacial patient because of high cost and

high radiation exposure than other craniofacial x-ray acquisition systems [19, 20].

The 2D and 3D MSCT protocol used in our study for determination of condylar height, condylar length (A-P dimension) and height of mandibular ramus values was created with the meaning to find precise criteria for quantified evaluation of morphological structures.

Our preliminary results revealed some relationships in the morphology of mandible and *processus condylaris*. Insignificant results in asymmetry between right and left side were obtained when comparing the height and length of condyle, as well as the length of mandibular ramus and mandibular body.

Statistically significant difference was found between the right and left side in the height of *processus condylaris* in patients without clinically evident asymmetry which could be considered in the individual planning of orthodontic and orthognatic patients that means that 2D and 3D CT reconstruction images data are especially helpful in the assessment of asymmetry [21].

Thus, we could assume that more adaptive remodeling has been in the structures of *processus condylaris*. Enlow [1] indicated that condyle functions, as a regional field of growth provide an adaption for its own localized growth circumstances, just like all the other regional fields accommodate their own particular localized growth circumstances. Although correlated of condyle there are two regional growth sites that are essentially separate and develop under different regional conditions and control [1].

It could be an explanation why we did not find consistent correlation between condylar height and mandibular ramus height; however more significant

Table 1. Mean values of condylar and mandibular measurements between right and left side (in mm)

Measurement	Right side		Left side		P value
	Mean	SD	Mean	SD	
Height of condyle	3.7	0.83	3.6	0.56	ns
Length of condyle	7.9	0.85	8.3	1.56	ns
Height of <i>processus condylaris</i>	18.7	3.54	17.1	3.96	0.057
Length of mandibulae	107.4	7.89	106.	8.34	0.05
Height of mandibular ramus	57.7	6.23	56.3	6.98	ns
Mandibular body length	66.9	6.09	66.6	5.93	ns

Ns – the difference is not statistically significant

Table 2. Correlation coefficients between condylar and mandibular measurements

Measurements	Condylar height		Condylar length		<i>Processus condylaris</i> height	
	Right side	Left side	Right side	Left side	Right side	Left side
Length of mandibulae	0.02	0.22	-0.36	-0.53	0.85	0.67
Height of mandibular ramus	-0.14	0.16	-0.5	-0.58	0.49	0.61
Mandibular body length	0.32	0.43	-0.07	-0.28	0.69	0.6

negative correlation has been observed in the interrelation between condylar length and mandibular ramus, whereas correlation between *processus condylaris* height and mandibular body length confirms significant positive interrelation. Although sexual dimorphism is known to be significant in condylar and mandibular measurements, in our study no attempt to evaluate females and males separately was performed because of the limited number of individuals in collect sample [24; 25]. Nevertheless, our results could be interpreted only as a tendency.

In general, further research on the application of 2D and 3D CT images in the assessment of condyle

and changes in mandibular morphology as part of craniofacial structure investigation is necessary.

CONCLUSION

The developed combined 2D and 3D MSCT investigation protocol for condylar and mandibular measurements provides precise and demonstrative quantitative images of condylar and mandibular structures and its dimensional relationships, which could be qualified as informative criteria for the individual treatment planning for patients with Class II division 1 subdivision malocclusion.

REFERENCES

- Enlow DH. Facial growth. 3rd ed. W.B. Saunders Co; 1990. p. 90-8.
- Björk A, Skieller V. Normal and abnormal growth of the mandible. A synthesis of longitudinal cephalometric implant studies over a period of 25 years. *Eur J Orthod* 1983;5:1-46.
- Arnett GW, Milam SB, Gottesman L. Progressive mandibular retrusion- idiopathic condylar resorption. Part I. *Am J Orthod Dentofacial Orthop* 1996; 110: 8-15.
- Arnett GW, Milam SB, Gottesman L. Progressive mandibular retrusion- idiopathic condylar resorption .Part II. *Am J Orthod Dentofacial Orthop* 1996; 110: 117-27.
- Peltola JS. Radiological variations in mandibular condyles of Finnish students, one group orthodontically treated and the other not. *Eur J Orthod* 1993;15: 223-7.
- Gianelly AA, Petras JC, Boffa J. Condylar position and Class II deep bite no overjet malocclusions. *Am J Orthod Dentofacial Orthop* 1989;96:428-32.
- Vidra MA, Rozema FR, Kostense PJ, Tuinzing DB. Observer consistency in radiographic assessment of condylar resorption. *Oral Surg Oral Med Oral Pathol Oral Radiol Endod* 2002; 93:399-403.
- Katsavrias EG, Halazonetis DJ. Condyle and fossa shape in Class II and Class III skeletal patterns: a morphometric tomographic study. *Am J Orthod Dentofacial Orthop* 2005;128:337-46.
- Katsavrias EG. Morphology of temporomandibular joint in subjects with Class II Division 2 malocclusions. *Am J Orthod Dentofacial Orthop* 2006;129:470-78.
- rtun J, Hollender LG, Truelove EL. Relationship between orthodontic treatment condylar position and internal derangement in the temporomandibular joint. *Am J Orthod Dentofacial Orthop* 1992;101:48-53.
- Ahn SJ, Kim TW, Lee DY, Nahm DS. Evaluation of internal derangement of the temporomandibular joint by panoramic radiographs compared with magnetic resonance imaging. *Am J Orthod Dentofacial Orthop* 2006;129:479-85.
- Raustia AM, Pyhtinen J. Morphology of the condyles and mandibular fossa as seen by computed tomography. *J Prosthet Dent* 1990;63:77-82.
- Ebner KA, Otis LL, Zakhary R., Danforth R.A. Axial temporomandibular joint morphology: A correlative study of radiographic and gross anatomic findings. *Oral Surg Oral Med Oral Pathol* 1990;69:247-52.
- Vitral RW, Telles CS. Computed tomography evaluation of temporomandibular joint alterations in Class II division 1 subdivision patients: condylar symmetry. *Am J Orthod Dentofacial Orthop* 2002;121:369-75.
- Vitral RW, Telles CS, Fraga MR, de Oliveira RS, Tanaka OM. Computed tomography evaluation of temporomandibular joint alterations in patients with Class II Division 1 subdivision malocclusions: Condyle- fossa relationship. *Am J Orthod Dentofacial Orthop* 2004;126:48-52.
- Cevidanes LH, Franco AA, Gerig G, Proffit WR, Slice DE, Enlow DH, et al. Comparison of relative mandibular growth vectors with high- resolution 3- dimensional imaging. *Am J Orthod Dentofacial Orthop* 2005;128:27-34.
- Miller A.J., Maki K., Hatcher D.C. New diagnostic tools in orthodontics. *Am J Orthod Dentofacial Orthop* 2004;126:395-6
- Harell WEJr, Hatcher DC, Bolt RL. In search of anatomical truth: 3- dimensional digital modeling and the future of orthodontics. *Am J Orthod Dentofacial Orthop* 2002;122:325-30.
- Swennen GR, Schutyser F. Three- dimensional cephalometry: spiral multi slice vs.cone- beam computed tomography. *Am J Orthod Dentofacial Orthop* 2006;130:410-16.
- Swennen GR, Schutyser F, Barth EL, De Groeve P, De Mey A. A new method of 3-D cephalometry Part I: The Anatomic Cartesian 3-D Reference system. *J Craniofac Surg* 2006;17:314-25.
- Halazonetis DJ. From 2- dimensional cephalograms to 3- dimensional computed tomography scans. *Am J Orthod Dentofacial Orthop* 2005;127:627-37.
- Hilgers ML, Scarfe WC, Scheetz JP, Farman AG. Accuracy of linear temporomandibular joint measurements with cone beam computed tomography and digital cephalometric radiography. *Am J Orthod Dentofacial Orthop* 2005;128:803-11.
- Cha JY, Mah J, Sinclair P. Incidental findings in the maxillofacial area with 3-dimensional cone-beam imaging. *Am J Orthod Dentofacial Orthop* 2007;132:7-14.
- Hoppenreijts TJM, Freihofer HPM, Stoelinga PJW, Tuinzing DB, van't Hof MA. Condylar remodelling and resorption after Le Fort I and bimaxillary osteotomies in patients with anterior open bite. *Int J Oral Maxillofac Surg* 1998;27:81-91.
- Hwang SJ, Haers PE, Seifert B, Sailer HF. Non- surgical risk factors for condylar resorption after orthognatic surgery. *J Craniofac Surg* 2002;32:103-11.

Received: 22 08 2007

Accepted for publishing: 24 09 2007