

# A 2-year follow-up study on standard length implants inserted into alveolar bone sites augmented with homografts

Maurizio Franco, Emanuela Tropina, Bruno De Santis, Alessandro Viscioni, Leone Rigo, Riccardo Guidi, Francesco Carinci

## SUMMARY

**Objective.** In the last decade, several investigators have reported that standard length implants (SLIs) have achieved excellent results but no report regarding SLIs (i.e. SLI, length=13 mm) inserted into alveolar bone sites previously augmented with frozen bone (FB) is available. The aim of this study was to evaluate the clinical outcome of SLIs inserted into alveolar bone sites previously augmented with FB.

**Patients and methods.** The survival and success rate of standard dental implants was evaluated after surgical placement into alveolar bone sites previously augmented with FB. The distance between Implant Abutment Junction and crestal bone level (i.e. delta IAJ) was measured to evaluate the peri-implant bone loss over time. Kaplan-Meier algorithm and Cox regression were used.

**Results.** The implant survival rate was 97.6% and no differences were detected among the studied variables by using implant loss. On the contrary, the Cox regression showed that implant surface (i.e. sandblasted and acid-etched-SLA- and CaPO<sub>4</sub> ceramic-blasted implants, p=0.0037), graft site (i.e. maxilla, p=0.0438) and prosthetic restoration (i.e. removable dentures, p=0.0003) correlated with a statistically significant reduced crestal bone loss (i.e. success rate).

**Conclusion.** SLIs had a high survival and success rate similar to those reported in previous studies of two-stage procedures in non-grafted bone. FB is a reliable material for alveolar reconstruction and implant insertion.

**Key words:** iliac crest, homograft, implant, length.

## INTRODUCTION

Thirteen-millimeter long fixtures are considered standard length implants (SLIs) and some reports describe their survival. Winkler et al. [1] analyzed a series of 2917 implants and concluded that SLIs have an intermediate survival rate (i.e. SVR – implants still in place at the end of the observation period) and success rate (i.e. SCR – reduced bone resorption around implant neck) if compared with short (i.e. diameter <13 mm) and long (i.e. diameter >13 mm)

implants. Levin et al. [2] focused on single tooth fixtures: on 1387 implants with an average follow-up period of more than 3 years there was an overall SVR of 93.1%. No statistically significant difference in survival was detected as regards length [2]. Ko et al. [3] performed a retrospective multicenter cohort study to collect long-term follow-up clinical data from dental records of 224 patients treated with 767 2-stage endosseous implants. All implants had hydroxyapatite-blasted surfaces. No differences of implant survival among different implant length were observed. A survival rate of 97.9% was detected after a mean of 4.5 years.

Although good clinical outcomes have been reported, especially in recent years, none focus on SLIs inserted into alveolar bone sites previously augmented with homologous frozen bone (i.e. FB).

Bone allograft transplantation has been performed in humans for more than one hundred years and is also being used increasingly by orthopedic surgeons [4].

<sup>1</sup>Dept of Maxillofacial Surgery, Civil Hospital, Castelfranco Veneto, Italy

<sup>2</sup>Maxillofacial Surgery, University of Ferrara, Ferrara, Italy

Maurizio Franco<sup>1</sup> – M.D.

Emanuela Tropina<sup>1</sup> – M.D.

Bruno De Santis<sup>1</sup> – M.D.

Alessandro Viscioni<sup>1</sup> – M.D.

Leone Rigo<sup>1</sup> – M.D.

Riccardo Guidi<sup>1</sup> – M.D.

Francesco Carinci<sup>2</sup> – Prof., M.D., Chair of Maxillofacial Surgery

Address correspondence to: Prof. Francesco Carinci, Arcispedale S. Anna, Corso Giovecca 203, 44100 Ferrara, Italy.

E-mail address: [crc@unife.it](mailto:crc@unife.it)

Many forms of banked bone allograft are available to the surgeon. Among the grafts available are frozen bone (FB), freeze-dried bone (FDB), and dematerialized fresh dried bone (DFDB). Each one of these grafts carries risks and has unique limitations and handling properties. In order to use these materials appropriately, the surgeon must be familiar with the properties of each and must feel confident that the bone bank providing the graft is supplying a safe and sterile graft [5].

Regarding the use of FB in Oral and Maxillofacial Surgery, only 2 articles are to be found in the literature [6, 7]. In 1992 Perrot [6] used autologous bone and implants to restore atrophic jaws. The survival rate was, after prosthetic restoration, of 95.8% (1 implant lost out of 29). In 2002 Rochanawutanon [7] demonstrated that even after the resection of big portions of the mandible FB can be used: he reported 4 cases with a follow-up of over 12 years.

The aim of this study was the evaluation of the clinical outcome of SLIs inserted into alveolar bone sites previously augmented with frozen bone.

## MATERIALS AND METHODS

### Patients

In the period between December 2003 and December 2006, 81 patients (52 females and 29 males) with a median age of 52.4 years were operated on at the Civil Hospital, Castelfranco Veneto, Italy. A total of 140 grafts were inserted. Twenty-seven (19.3%) FBs were inserted in the mandibles and 113 (80.7%) in the maxillae. One hundred and three (73.6%), 26 (18.6%) and 11 (7.9%) were inlay, onlay and veneer grafts, respectively. No membrane was used. Among the 81 patients, 61 subjects (38 females and 23 males) with a median age of 53.5 years were treated with SLIs. The remaining 20 patients received implants of different length (longer or shorter than 13 mm) and were dropped out from this study. Informed written consent approved by the local Ethics Committee was obtained from patients to use their data for research purpose. The mean post-loading follow-up was 24 months (range 1 to 45).

Homologue FB grafts were previously inserted into patient's jaws under general anesthesia. Usually the mean post-grafting period was 6 months before implant surgery and the final prosthetic restoration was delivered after an additional 6 months.

Subjects were screened according to the following inclusion criteria: controlled oral hygiene, the absence of any lesions in the oral cavity, sufficient residual bone volume (i.e. a residual bone of less than 5

mm wide and 14 mm high); in addition, the patients had to agree to participate in a post-operative check-up program.

The exclusion criteria were as follows: insufficient bone volume, a high degree of bruxism, smoking more than 20 cigarettes/day and excessive consumption of alcohol (i.e. more than half a liter per day), localized radiation therapy of the oral cavity, antitumor chemotherapy, liver, blood and kidney diseases, immunosuppressed patients, patients taking corticosteroids, pregnant women, inflammatory and autoimmune diseases of the oral cavity, poor oral hygiene.

### Graft material

The FB – obtained from the Veneto Tissue Bank in Treviso (Italy) – is a mineralized, non-irradiated, only disinfected and frozen homologous bone. The bone harvesting is obtained from the anterior and posterior iliac crest. The bone is then disinfected, for at least 72 hours at  $-4^{\circ}\text{C}$ , in a polychemotherapeutic solution of vancomycine, polymyxine, glazidine and lincomycine, following that the sample is irrigated with a sterile saline solution. The sample is then subdivided into cortico-medullary blocks, packed in double sterile casing and frozen at  $-80^{\circ}\text{C}$  (Veneto Region Law n. 3948, 15 December 2000).

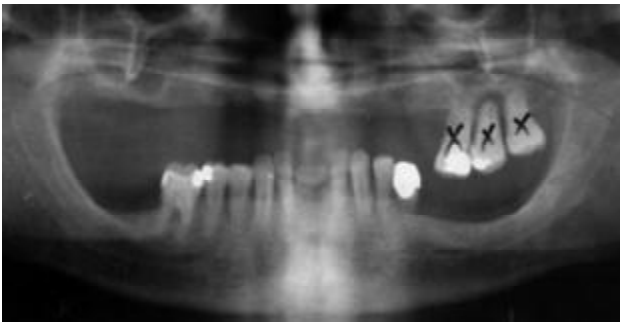
### Data collection

Before surgery, radiographic examinations were done with the use of orthopantomograph and CT scans.

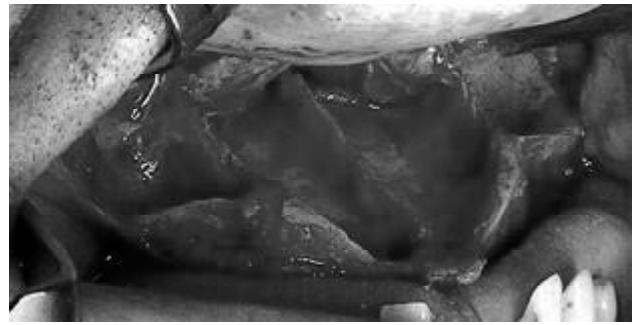In each patient, peri-implant crestal bone levels were evaluated by the calibrated examination of ortopantomograph x-rays. X-ray examinations were done and measurements were recorded before surgery, after surgery and at the end of the follow-up period. The measurements were carried out mesially and distally to each implant, calculating the distance between the implant-abutment junction and the most coronal point of contact between the bone and the implant. The bone level recorded just after the surgical insertion of the implant was the reference point for the following measurements. The measurement was rounded off to the nearest 0.1 mm. A peak Scale Loupe with a magnifying factor of seven times and a scale graduated in 0.1 mm was used.

Peri-implant probing was not performed since controversy still exists regarding the correlation between probing depth and implant success rates [8, 9].


The implant success rate (SCR) was evaluated according to the following criteria: (a) absence of persisting pain or dysesthesia; (b) absence of peri-im-



**Fig. 1.** Orthopantomograph before surgery



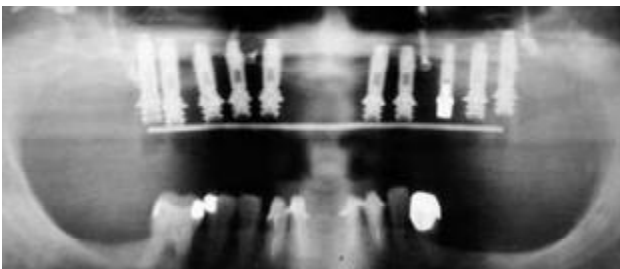
**Fig. 2.** Le Fort I osteotomy after residual teeth extraction



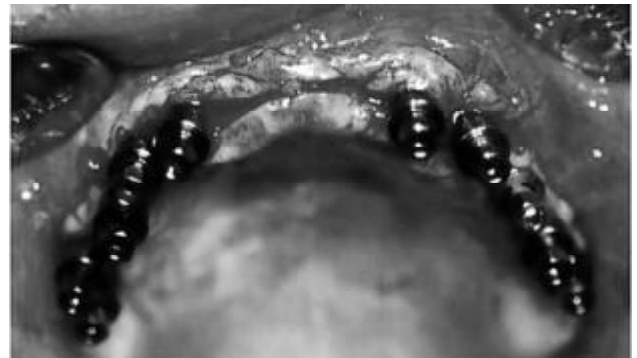**Fig. 3.** Preparation of shape and dimension of homografts



**Fig. 4.** Four homografts are fixed in the upper jaw by means of screws



**Fig. 5.** Orthopantomograph showing the inserted implants



**Fig. 6.** Ten implants are inserted after 4 months

plant infection with suppuration; (c) absence of mobility; and (d) absence of persisting peri-implant bone resorption greater than 1,5 mm during the first year of loading and 0,2 mm/years during the following years [10].

### Implants

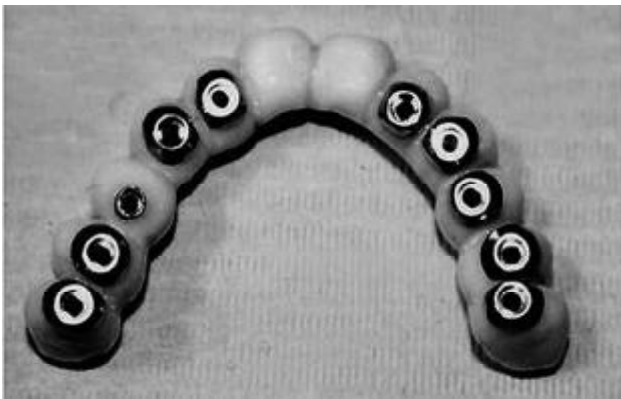
A total of 208 SLIs were inserted in 61 patients: 18 (8.7%) in the mandible and 190 (91.3%) in the maxilla. There were 65 Double etched (3i implants, Biomet Inc., US), 26 Grit blasted (Astra implants, Astra Tech Inc., Sweden), 2 Grit blasted and acid etched (Frialit implants, Friadent, Dentsply Inc., US), 62 Anodic oxidized (Nobel Biocare implants, TiUnite, Nobelbiocare Inc., US), 32 CaPO<sub>4</sub> ceramic-blasted (RBM implants, Lifecore Biomedical Inc., US), 20 Sandblasted and acid-etched (i.e. SLA – Sweden &

Martina, Sweden & Martina Spa, IT) and 1 Grit blasted and acid etched (ITI Implants, Straumann Inc., US).

Implant diameter ranged from 3.0 to 5.0 mm. Implants were inserted to replace 19 incisors, 15 cuspids, 89 premolars and 85 molars.

### Surgical and prosthetic technique

All patients underwent the same surgical protocol. An antimicrobial prophylaxis was administered with 500 mg Amoxicillin twice daily for 5 days starting 1 hour before surgery. Local anesthesia was induced by infiltration with articaine/epinephrine and post-surgical analgesic treatment was performed with 100 mg Nimesulid (Helsinn Healthcare S.A. Switzerland) twice daily for 3 days. Oral hygiene instructions were provided.

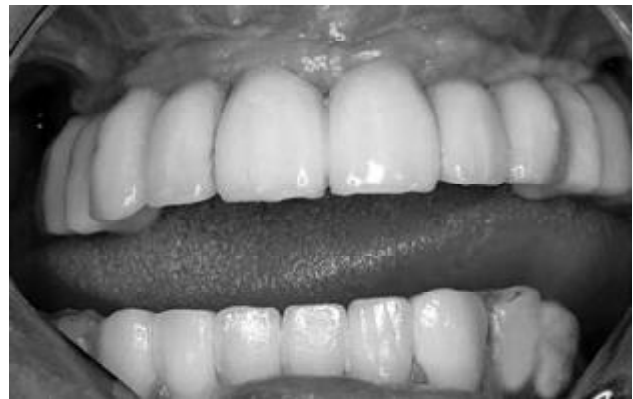

**Fig. 7.** Full arch prosthesis

After making a crestal incision a mucoperiosteal flap was elevated. The implant platform was positioned at the alveolar crest level. Sutures were removed 14 days after surgery. After 24 weeks from implant insertion, the provisional prosthesis was provided and the final restoration was usually delivered within an additional 8 weeks. The number of prosthetic units (i.e. implant/crown ratio) was about 0.8. All patients were included in a strict hygiene recall program (Fig. 1-8).

#### Statistical analysis

Since only 5 out of 208 implants were lost (i.e. SVR=97.6%) and no statistical differences were detected among the studied variables by using SVR, no or reduced crestal bone resorption was considered an indicator of SCR to evaluate the effect of



**Fig. 8.** The final oral rehabilitation

several host-, implant-, and occlusion-related factors.

The difference between the implant abutment junction and the bone crestal level was defined as the Implant Abutment Junction (IAJ) and calculated at the time of operation and during follow-up. The delta IAJ is the difference between the IAJ at the last check-up and the IAJ recorded just after the operation. Delta IAJ medians were stratified according to the variables of interest.

Disease-specific survival curves were calculated according to the product-limit method (Kaplan-Meier algorithm) [11]. Time zero was defined as the date of the insertion of the implant. Implants, which were still in place, were included in the total number at risk of loss only up to the time of their last follow-up. Therefore, the survival rate only changed when implant loss

**Table 1.** Distribution of series the number of cases is out of parenthesis whereas the median delta IAJ is in parenthesis

Graft site	Implant site	Implant diameter (mm)	Implant surface	Prosthetic Type
Mandible 18 (2.4)	Incisors 19 (2.3)	Diameter <3.75 mm 54 (2.1)	Double etched 65 (2.1)	None 28 (1.7)
Maxilla 190 (2.0)	Cuspids 15 (2.2)	Diameter =3.75 mm 80 (1.9)	Grit blasted 26 (3.1)	Fixed prosthesis 152 (2.1)
-	Premolars 89 (1.8)	Diameter >3.75 mm 74 (2.1)	Grit blasted and acid etched 2 (4.3)	Removable dentures 28 (2.0)
-	Molars 85 (2.0)	-	Anodic oxidized 62 (2.0)	-
-	-	-	CaPO <sub>4</sub> ceramic-blasted 32 (1.3)	-
-	-	-	SLA 20 (1.2)	-
-	-	-	Grit blasted and acid etched 1 (2.0)	-

**Table 2.** Failed implants

Implant diameter (mm)	Implant length (mm)	Graft site	Implant site	Implant surface	No. of months post implant insertion	Prosthesis
3.5	13	Maxilla	26	Double etched	4	None
3.5	13	Maxilla	16	Double etched	4	None
3.5	13	Maxilla	26	Anodic oxidized	1	None
3.75	13	Maxilla	26	CaPO <sub>4</sub> ceramic-blasted	6	None
4.3	13	Maxilla	26	Anodic oxidized	1	None

occurred. The calculated survival rate was the maximum estimate of the true survival curve. Log rank test was used to compare survival curves, generated by stratifications for a variable of interest.

Cox regression analysis was then applied to determine the single contribution of covariates on survival rate. Cox regression analysis compares survival data while taking into account the statistical value of independent variables, such as age and sex, on whether or not an event (i.e. implant loss) is likely occur. If the associated probability was less than 5% ( $p < 0.05$ ), the difference was considered statistically significant. In the process of doing the regression analysis, odds ratio and 95% confidence bounds were calculated. Confidence bounds did not have to include the value «1» [12]. Stepwise Cox analysis allowed us to detect the variables most associated with implant survival and/or success.

## RESULTS

Table 1 reports the median delta IAJ according to the studied variables.

Five implants were lost in the post-operative period (within 6 months) and Table 2 describes their characteristics.

The Kaplan Meier algorithm demonstrates that implant surface (Log rank=28.96,  $df=6$ ,  $p=0.001$ ) and type of prosthetic restoration (Log rank test=10.01,  $df=2$ ,  $p=0.006$ ) were statistically different.

Table 3 shows that implant surface (i.e. SLA and CaPO<sub>4</sub> ceramic-blasted surfaces – Table 1), grafted site (i.e. maxilla) and type of prosthetic restoration (i.e. removable dentures) correlated with a statistically significant lower delta IAJ (i.e. reduced crestal bone loss,  $p < 0.05$ ) and thus a better clinical outcome. No differences were detected among diameters. Also

**Table 3.** Output of Cox regression reporting the variables associated statistically with delta IAJ by evaluating delta IAJ (i.e. SCR)

Variable	Significance (P<0.05)	95% Confidence Interval	
		Lower	Upper
Age	0.2988	0.9860	1.0470
Gender	0.0375	0.3191	0.9665
Graft site	0.0438	1.0253	5.9631
Implant site	0.8400	0.7627	1.3954
Implant diameter	0.8470	0.6894	1.3570
Implant surface	0.0037	0.6906	0.9309
Type of restoration	0.0003	0.2025	0.6203

implant site does not make a statistically significant difference.

## DISCUSSION

The identification of guidelines for long term SVR and SCR (i.e. good clinical, radiological and aesthetic outcome) are the main goals of the recent research. Usually variables influencing the final result are grouped as (a) surgery-, (b) host-, (c) implant-, and (d) occlusion-related factors [13]. The surgery-related factors comprise several variables such as an excess of surgical trauma like thermal injury, bone preparation, drill sharpness and design [14]. Bone quality and quantity are the most important host-related factors [15], while design, surface coating, diameter and length are the strongest implant-related factors [16, 17]. Finally, quality and quantity of force [18] and prosthetic design [19] are the variables of interest among the occlusion-related factors. All these variables are a matter of scientific investigation since they may affect the clinical outcome.

In general, length, surface, and diameter are considered to be relevant fixture-related factors. In the present study they had no impact on SVR but implant surface appears to be a relevant factor as regards SCR (Table 1): among our failures two were Double etched, two were Anodic oxidized and one CaPO<sub>4</sub> ceramic-blasted implants.

Bone quality, a host-related factor, is believed to be the strongest predictor of outcome. It is well known that the mandible (especially the interforaminal region) has better bone quality than the maxilla, and this fact is probably the reason why several reports are available regarding a critical occlusal procedure (i.e. immediately loaded) of implants inserted into the mandible with a high SVR [15]. Our data shows that FB is an effective material to restore alveolar ridge volume as only 5 implants were lost. In addition, although no difference was detected as regards SVR, a better outcome was revealed for the SCR in the mandible. This fact is in contrast with those of previous reports but could be due to the different surgical techniques employed: the mandible and maxillae were grafted with onlay and inlay, respectively. This difference gives an advance to maxillary FB due to better blood supply and bone contact. Clayman [20], reported long term good results in maxilla but autografts were used.

The FB inserted in jaws is widely used by orthopedics and no adverse effects are recorded till now. It is possible, however, that some patients could have allergic reaction for someone of drugs used for bone preparation (i.e. vancomycine, polymyxine, glazidine

and lincomycine although thereafter the sample is irrigated with a sterile saline solution) and this fact should be investigated by surgeons during the patient's admission to Department.

Among occlusal-related factors, no differences were detected as regards SVR. However a better outcome was detected for unloaded bone and removable dentures (Table 1). This result is not in line with results from other studies and could be related to the limited number of removable dentures reported here [21]. Additional studies on larger series are needed before a conclusion can be clearly stated.

## CONCLUSION

FB is a reliable grafting material for alveolar crest reconstruction. SLIs inserted into alveolar bone sites previously augmented with FB have a cumulative survival rate of 97.6%. Both survival rate and success

rate (i.e. crestal bone resorption) of SLIs inserted in augmented alveolar process with FB are similar to those reported for SLIs inserted in native bone with the same surgical technique (i.e. two-stage procedures). SLIs inserted into alveolar bone sites previously augmented with FB can be considered reliable devices for oral rehabilitation although a higher marginal bone loss is to be expected in the mandible and in case of fixed restoration.

## ACKNOWLEDGEMENTS

This work was supported by FAR from the University of Ferrara (F.C.), Ferrara, Italy and from Regione Emilia Romagna, Programma di Ricerca Regione Universita' 2007-2009 Area 1B: Patologia osteoarticolare: ricerca pre-clinica e applicazioni cliniche della medicina rigenerativa Unità Operativa n. 14.

## REFERENCES

1. Winkler S, Morris HF, Ochi S. Implant survival to 36 months as related to length and diameter. *Ann Periodontol* 2000;5:22-31.
2. Levin L, Sadet P, Grossmann Y. A retrospective evaluation of 1,387 single-tooth implants: a 6-year follow-up. *J Periodontol* 2006;77:2080-3.
3. Ko SM, Lee JK, Eckert SE, Choi YG. Retrospective multicenter cohort study of the clinical performance of 2-stage implants in South Korean populations. *Int J Oral Maxillofac Implants* 2006;21:785-8.
4. Tomford WW, Mankin HJ. Bone banking. Update on methods and materials. *Orthop Clin North Am* 1999;30:565-70.
5. Hardin CK. Banked bone. *Otolaryngol Clin North Am* 1994;27:911-25.
6. Perrot DH. The use of fresh frozen allogenic bone for maxillary and mandibular reconstruction. *Int J Oral Maxillofac Surg* 1992;21:260-5.
7. Rochanawutanon S. Long term follow up of reconstruction of allogenic mandibular bone crib packed with autogenous particulate cancellous bone marrow. *Cell Tissue Bank* 2002;3:183-97.
8. Quirynen M, van Steenberghe D, Jacobs R, Schotte A, Darius P. The reliability of pocket probing around screw-type implants. *Clin Oral Impl Res* 1991;2:186-192.
9. Quirynen M, Naert I, van Steenberghe D, Teerlinck J, Dekeyser C, Theuniers G. Periodontal aspects of osseointegrated fixtures supporting an overdenture. A 4-year retrospective study. *J Clin Periodontol* 1991;18:719-28.
10. Albrektsson T, Zarb GA. Determinants of correct clinical reporting. *Int J Prosthodont* 1998;11:517-21.
11. Dawson-Saunders B, Trapp RG, editors. Basic & Clinical Biostatistic. Norwalk: Appleton & Lange; 1994.
12. Cox DR, Oakes D, editors. Analysis of survival data. New York: Chapman & Hall; 1984.
13. Gapski R, Wang HL, Mascarenhas P, Lang NP. Critical review of immediate implant loading. *Clin Oral Impl Res* 2003;14:515-27.
14. Eriksson AR, Albrektsson T, Albrektsson B. Heat caused by drilling cortical bone. Temperature measured in vivo in patients and animals. *Acta Orthop Scand* 1984;55: 629-31.
15. Misch CE. Bone density: a key determinant for clinical success. In: Misch CE, editor. Contemporary implant dentistry. Chicago: Mosby; 1999. p. 109-18.
16. Zinsli B, Sagesser T, Mericske E, Mericske-Stern R. Clinical evaluation of small-diameter ITI implants: a prospective study. *Int J Oral Maxillofac Implants* 2004;19:92-9.
17. Vigolo P, Givani A, Majzoub Z, Cordioli G. Clinical evaluation of small-diameter implants in single-tooth and multiple-implant restorations: a 7-year retrospective study. *Int J Oral Maxillofac Implants* 2004;19:703-9.
18. Comfort MB, Chu FC, Chai J, Wat PY, Chow TW. A 5-year prospective study on small diameter screw-shaped oral implants. *J Oral Rehabil* 2005;32:341-5.
19. Colomina LE. Immediate loading of implant-fixed mandibular prostheses: a prospective 18-month follow-up clinical study - preliminary report. *Implant Dent* 2001;10:23-9.
20. Clayman L. Implant reconstruction of the bone-grafted maxilla: review of the literature and presentation of 8 cases. *J Oral Maxillofac Surg* 2006;64:674-82.
21. Franco M, Viscioni A, Rigo L, Guidi R, Brunelli G, Carinci F. Iliac crest fresh frozen homografts used in pre-prosthetic surgery: a retrospective study. *Cell Tissue Bank* 2008 Dec 2. [Epub ahead of print]

Received: 11 08 2008  
Accepted for publishing: 22 12 2008