

## Focal epithelial hyperplasia: Case report

*Alina Puriene, Arunas Rimkevicius, Mindaugas Gaigalas*

### SUMMARY

The purpose of the present article is to present a 15 year-old patient with focal epithelial hyperplasia and to review the references on the subject-related etiological, pathological, diagnostic and treatment aspects. Focal epithelial hyperplasia is a rare human papilloma virus (HPV) related to oral lesion with very low frequency within our population. Surgical treatment with a biopsy was performed, acanthosis and parakeratosis are consistent histopathological features, since the patient had no history of sexual contact and HIV infection, the virus was probably acquired from environmental sources.

**Key words:** focal epithelial hyperplasia, heck's disease, oral mucosa, papilloma virus.

### INTRODUCTION

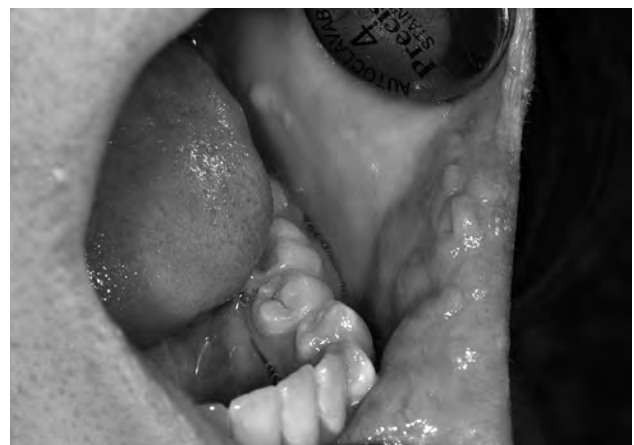Focal epithelial hyperplasia (FEH) or Heck's disease is a rare contagious disease caused by human papilloma virus (HPV) types 13 or 32 (1,5) and was first described in 1965 from the observation of isolated or multiple soft papular and nodular eruptions on the oral mucosa of Navajo Xavante Indian and Alaska Eskimo children (2). The condition occurs in numerous populations and ethnic groups, is more common in Native Americans, certain other ethnic groups and children. The frequency of this disease is variable with a wide range from 0.002 to 35% depending on the population studied and geographic region of the world. FEH lesions have been detected worldwide (3, 4) but it is rare disease in Europe. In a study on oral lesions among an adult Swedish population of 20,333 subjects, a prevalence of 0.1% for FEH was reported (1). A higher incidence in close communities and among family members indicates infectious pathogenesis it is also may be an oral manifestation of HIV infection. This condition is characterized by the occurrence of multiple small papules or nodules from 5 to 10 mm diameter in oral cavity. The lesions are painless, tend to disappear spontaneously, and are predominantly found on the lower lip, buccal

mucosa and tongue, and less often on the upper lip, gingiva and palate (6, 7).

The present report describes 15-year-old patient with no HIV infection with typical oral mucosa and histopathological features, in which the lesions had persisted for 2 years.

### CASE PRESENTATION

This report illustrates how to recognize, diagnose and manage patients with focal epithelial hyperplasia. 15-year-old teenager girl applied to Žalgiris Clinic of Vilnius University Hospital and complained of a group growing lesions on the cheek and lip mucosa. Lesions had been first noticed almost two years ago, which were painless and soft and had appeared spontaneously. Oral examination revealed several sessile, normochromic tissue



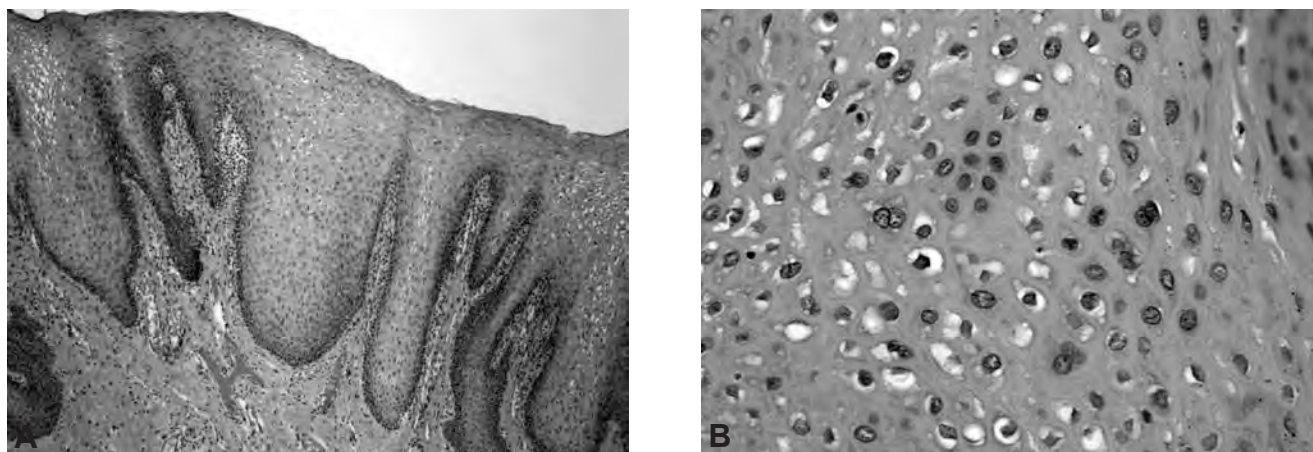
**Fig. 1.** Labial mucosa of a 15-year-old teenager girl shows multiple slightly elevated papulonodular lesions

*\*Institute of Odontology, Faculty of Medicine, Vilnius University, Vilnius, Lithuania*

*Alina Puriene\* – D.D.S., PhD, prof.  
Arunas Rimkevicius\* – D.D.S.  
Mindaugas Gaigalas\* – D.D.S.*

*Address correspondence to Prof. Alina Puriene, Zalgiris Clinic Vilnius University Hospital, Zalgirio 117, LT-08217 Vilnius, Lithuania.*

*E-mail address: alina.puriene@mfvu.lt*



**Fig. 2.** A – photomicrograph demonstrates acanthosis, parakeratosis and epithelial hyperplasia  $\times 100$ . B – koilocytic cells are visible within the epithelium. Hematoxylin and eosin  $\times 200$ .

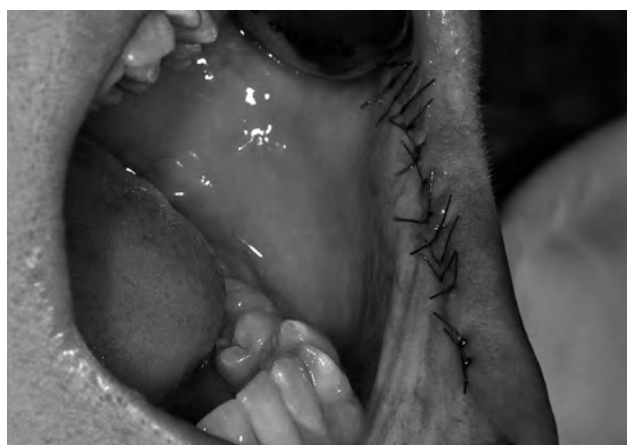proliferations on the cheek and lip mucosa (Fig. 1). Diagnostic of such oral lesions was based on the clinical evaluation, confirmed by biopsy. Such oral lesions may be an oral manifestation of HIV infection, thus additional laboratory diagnostics for HIV infection and other sexually transmitted diseases were requested. The tests for other diseases were negative. For clear diagnosis, esthetic and traumatic reasons relating to visible labial lesions; excision biopsy was performed under local anesthesia on the cheek and lip mucosa. Histopathological examination of the oral lesion performed by the National Center of Pathology revealed hyper keratinized epithelium exhibiting hyperplasia and deep papillomatous projections. Acanthosis and parakeratosis are consistent findings. Some squamous cells exhibited mitotic figures, called koilocytic cells (Fig. 2). After the surgical procedure/intervention (Fig. 3) and a subsequent course of treatment (Fig. 4) the patient was highly satisfied; however a recurrence of the disease remains of concern and highly probable. Therefore, it is of primary importance, before

referring to surgical treatment, to first inform the patient of a possible relapse of his condition.

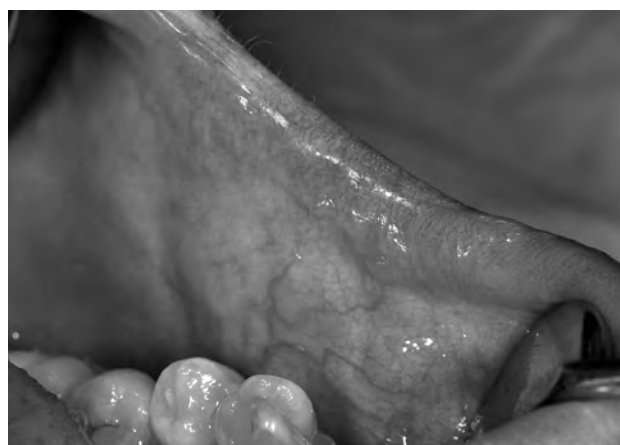### DISCUSSION

Human papilloma virus is a DNA-containing viruses that replicate the flat epithelial cell nuclei. Infected with HPV, infection can result in subclinical course or latent form of HPV-related lesions which may appear and disappear or persist for a long time. The mucosa may be 8-10 times thicker than normal. It is impossible to predict when and if lesions will recur or where new lesions may emerge, it is also not yet known whether recurrence of the lesions is related to latent infection, changes in immune response or new infections, more studies are needed.

There seems to be no malignant transformation potential of FEH (8, 9), but it may be an oral manifestation of HIV infection, so our primarily tasks are early disease diagnosis and research on possible HIV infection. Setting the diagnosis of



**Fig. 3.** The wound is sutured with Vicryl 5-0 sutures



**Fig. 4.** Patient after treatment

FEH is extremely important because of the need for the differential diagnosis with other conditions, namely inflammatory fibrous hyperplasia, inflammatory papillary hyperplasia, verruciform xanthoma, verrucous carcinoma, Cowden's disease, condyloma acuminatum, and focal dermal hypoplasia syndrome (Goltz-Gorlin syndrome) (2,7). FEH is a benign condition that heals spontaneously and therefore requires no treatment, except in some cases of functional (e.g., lesions that are constantly traumatized on biting) or aesthetic impairment (10). Several treatment modalities have been proposed for

FEH, as scalpel surgery, cryosurgery, laser ablation, cauterization and topical treatments with retinoic acids or interferon (8, 11) with no evidence of any treatment success differences. Follow-up is important for evaluation of treatment success.

## CONCLUSION

FEH is a condition caused by human papilloma virus, quite uncommon in European countries. Early detection of the disease is the most important factor in the prevention of its further development.

## REFERENCES

- Pfister H, Heltich J, Runne U, Chiff GN. Characterization of human papillomavirus type 13 from focal epithelial Heck lesions. *J Virol* 1983; 47:363-6.
- Archard HO, Heck JW, Stanley HR. Focal epithelial hyperplasia: an unusual oral mucosal lesion found in Indian children. *Oral Surg Oral Med Oral Pathol* 1965;20:201-12.
- Axell T. A prevalence study of oral mucosal lesions in an adult Swedish population. *Odontol Revy* 1976;27:1-77.
- Petzoldt D, Pfister H. HPV 1 DNA in lesion of focal epithelial hyperplasia Heck. *Arch Dermatol Res* 1980;268:313-4.
- Moerman M, Danielides VG, Nousia CS, Van Wanseele F, Forsyth R, Vermeersch H. Recurrent focal epithelial hyperplasia due to HPV13 in an HIV positive patient. *Dermatology* 2001;203:339-41.
- Praetorius F. HPV-associated diseases of oral mucosa. *Clin Dermatol* 1997; 15:399-413.
- Terezhalmay GT, Riley CK, Moore WS. Focal epithelial hyperplasia (Heck's disease). *Quintessence Int* 2001;32:664-5.
- Jablonska S, Majewski S. Demonstration of HPV 24 in longstanding Heck's disease with malignant transformation. *Eur J Dermatol* 2000;10:235-6.
- Flaitz CM. Focal epithelial hyperplasia: A multifocal oral human papillomavirus infection. *Pediatr Dent* 2000;22:153-4.
- Durso BC, Pinto JM, Jorge J, de Almeida OP. Extensive focal epithelial hyperplasia: case report. *J Can Dent Assoc* 2005;71:769-71.
- Syrjanen K, Happonen RP, Syrjanen S, Caloni B. Human papilloma virus (HPV) antigens and local immunologic reactivity in oral squamous cell tumors and hyperplasias. *Scand J Dent Res* 1984;92:358-70.
- Borborema-Santos CM, Castro MM, Santos PJ, Talhari S, Astolfi-Filho S. Oral focal epithelial hyperplasia: report of five cases. *Braz Dent J* 2006;17:79- 82.
- Hall C, McCullough M, Angel C, Manton D. Multifocal epithelial hyperplasia: a case report of a family of Somalian descent living in Australia. *Oral Surg Oral Med Oral Pathol Oral Radiol Endod* 2006;109:20-4.
- Martins WD, de Lima AA, Vieira S. Focal epithelial hyperplasia (Heck's disease): report of a case in a girl of Brazilian Indian descent. *Int J Paediatr Dent* 2006;16:65-8.
- Horewicz VV. Human papillomavirus-16 prevalence in gingival tissue and its association with periodontal destruction: a case-control study. *J Periodontol* 2010; 4:562-68.
- Syrjanen S. Human papillomavirus infections and oral tumors. *Med Microbiol Immunol* 2003;3:123-28.
- Ledesma-Montes C, Vega-Memije E, Garcés-Ortiz M, Cardiel-Nieves M, Juárez-Luna C. Multifocal epithelial hyperplasia. Report of nine cases. *Med Oral Patol Oral Cir Bucal* 2005;10:394-401.
- Terezhalmay GT, Riley CK, Moore WS. Focal epithelial hyperplasia (Heck's disease). *Quintessence Int* 2001;32:664-5.
- Maryam Alsadat Hashemipour, Ali Shoryabi, Shahrzad Adhami, Hoda Mehrabzadeh Honarmand. Extensive Focal Epithelial Hyperplasia. *Arch Iran Med* 2010;13:48-52.
- Alakloby OM, Randhawa MA. Case report: Oral focal epithelial hyperplasia (Heck's disease). *J Pan-Arab League Dermatol* 2009;20:52-5.
- Segura-Saint-Gerons R, Toro-Rojas M, Ceballos-Salobreña A, Aparicio-Soria JL, Fuentes-Vaamonde H. Focal epithelial hyperplasia. A rare disease in our area. *Med Oral Patol Oral Cir Bucal* 2005;10:128-31.
- Artac H, Gokturk B, Bozdemir SE, Toy H, van der Burg M, Santisteban I, et al. Late-onset adenosine deaminase deficiency presenting with Heck's disease. *Eur J Pediatr* 2010;169:1033-6.
- Dos Santos-Pinto L, Giro EM, Pansani CA, Ferrari J, Masucato EM, Spolidorio LC. An uncommon focal epithelial hyperplasia manifestation. *J Dent Child* 2009;76:233-6.
- Flaitz CM. Focal epithelial hyperplasia: a multifocal oral human papillomavirus infection. *Pediatr Dent* 2000;22:153-4.

Received: 05 05 2011

Accepted for publishing: 23 09 2011