

# Symmetry of external auditive meatus. A pilot study on human skulls

*Simona Mizgiryte, Julius Vaitelis, Arunas Barkus, Linas Zaleckas, Rolandas Pletkus, Adomas Auskalnis*

## SUMMARY

**Objectives.** To evaluate the perpendicularity of the line connecting external auditive meatus to the midsagittal plane and the palatal suture as a midsagittal symmetry reference line.

**Setting and Sample Population** – 62 randomly chosen human skulls from osteological collection (Vilnius University).

**Material and Methods.** The skulls were photographed (Nikon 40 D, Nikkor lens 50 mm) from basal, frontobasal and frontal views. Photos were analysed with Adobe Photoshop CS5 (Adobe). The first line connected frontal points of external auditive meatus and the angle to the midsagittal plane was measured. The second line (the palatal suture) was compared to the median sagittal plane. Data was analysed with SPSS 17 (IBM).

**Results.** The mean value for the angles of the line between the external auditive meatus and the midsagittal plane in basal views was 90.12° (SD=1.48°) and in frontobasal 90.36° (SD=2.25°). No statistically significant differences were found between groups of age and sex. The inter-rater agreement for evaluation of the adequacy of palatal suture with the midsagittal plane was high (Cohen's Kappa 0.702 (p<0.05)) as well as the coincidence of both lines in basal and frontobasal views (90.3% and 85.5% respectively).

**Conclusion.** Considering the limits of this study the angle between external auditive meatus and midsagittal skull plane has a characteristic fluctuating asymmetry. The congruence of palatal suture and midsagittal plane is debatable.

**Key words:** asymmetry, palatal suture, skull.

## INTRODUCTION

Contemporary dentistry uses different skull reference lines and points for aesthetical and functional dental reconstructions, visual treatment planning

<sup>1</sup>Department of Prosthodontics, Institute of Odontology, Faculty of Medicine, Vilnius University, Vilnius, Lithuania

<sup>2</sup>Department of Anatomy, Histology and Anthropology, Faculty of Medicine, Vilnius University, Vilnius, Lithuania

<sup>3</sup>Department of Oral and Maxillofacial Surgery, Institute of Odontology, Faculty of Medicine, Vilnius University, Vilnius, Lithuania

<sup>4</sup>Clinic of Dental and Oral Pathology, Faculty of Odontology, Lithuanian University of Health Sciences, Kaunas, Lithuania

*Simona Mizgiryte*<sup>1</sup> – D.D.S.

*Julius Vaitelis*<sup>1</sup> – D.D.S.

*Arunas Barkus*<sup>2</sup> – assoc. prof.

*Linas Zaleckas*<sup>3</sup> – D.M.S., PhD, assoc. prof.

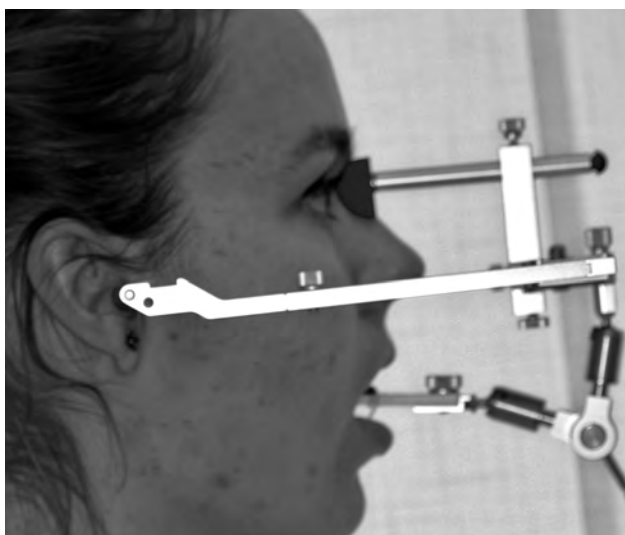
*Rolandas Pletkus*<sup>1</sup> – D.D.S., lecturer

*Adomas Auskalnis*<sup>4</sup> – D.D.S.

Address correspondence to Dr. Simona Mizgiryte, Department of Prosthodontics, Institute of Odontology, Faculty of Medicine, Vilnius University, Žalgirio Str. 115-217, 08217, Vilnius, Lithuania.  
E-mail address: simona.mizgiryte@gmail.com

(1-5). One of the daily used referential instrument is a facebow. It is a calliper-like instrument used to record the spatial relationship of the maxillary arch to some anatomic reference point or points and then transfer this relationship to an articulator; it orients the dental cast in the same relationship to the opening axis (mandibular terminal hinge axis) of the articulator and reference planes in sagittal plane (6) (Camper's, Frankfort or Patient horizontal plane). Facebow's (earbows) terminal parts (olivas) are placed into the external auditive meatus (lat. *meatus acusticus externus*), the frame is stabilised by the nasion bar, the bite fork is connected with a tridimensional joint and screwed (Fig.1). This position of maxilla is transferred to articulator (Fig. 2).

Facebow includes several highly discussed problems. Firstly, one reference line it works according to is the arbitrary mandibular hinge axis. As it is arbitrary, it differs in every patient and transferring it to mean values articulator can cause inaccuracies of occlusion in dental reconstructions (7-11).



**Fig. 1.** Face-bow

Secondly, there is a degree of human face soft-tissue (12-15) and facial skull asymmetry (16-18), especially in the middle (*tragus*) and lower (*gonion*) thirds of the face (19). Facial symmetry is defined as the correspondence in size, form, and arrangement of the facial features on opposite sides of the median sagittal plane (20). The external auditory meatus can be asymmetric in horizontal and frontal planes of a skull. Facebow has equal framework parts and standard nasion bar support, articulator also includes only symmetrical elements. When a standard symmetric facebow is positioned in an asymmetric surrounding by soft tissue auditory meatus, the position of maxilla is transferred with errors on the sagittal and the long axis resulting dental midline to be not adequate with the midsagittal plane, one side of the dental arch longer than another and the occlusion functionally and aesthetically not proper (21).

There are not enough studies analysing the perpendicularity of the line connecting both the external auditory meatus to the midsagittal skull plane. Zadurska *et al.* (22) used computer to assess symmetry for right and left sides of the maxillary dental arch, zygomatic arch and cranial base by comparing angular values derived from basion. But they made no conclusions about human skull symmetry. Rodrigues *et al.* (23, 24) concluded about different distances between condylar process to midsagittal plane at statistically significant differences between the right and left sides. There are also reports about the right-left symmetry of glenoid fossa, postglenoid tubercle and tympanum-canal but not the symmetry of their position (25-27).

Another cast mounting system Headlines (Jensen dental, USA) uses bipupilar line, midsagittal line, Camper's plane and palatal suture (lat. *sutura palatina mediana*) for maxillary cast mounting (20). Palatal



**Fig. 2.** Position of the maxillary cast in the articulator.

suture is visible in good impressions and dental casts so it may be as a reference line for mounting. But there is very little data about the adequacy of the secondary palatal suture with the midsagittal skull plane. De Araujo *et al.* (28) agreed that maxillary and mandibular dental midlines, palatal suture on the casts and median sagittal plane on the radiographs are almost coincident. Ferrario *et al.* (29) calculated the deviation of the palatal suture from the midline in the investigation of effect of ethnicity and age on palatal size and shape, but did not present conclusions about this measurement.

In scientific literature exist alternative reference planes for cast mounting, as an alternative for times proven cast mounting planes. Wong *et al.* (42) presented a voxel-based median plane, with which was helped to maintain postoperative mandibular deviation and occlusion plane.

The aim of this study is to assess if the line connecting the external auditory meatus is perpendicular to midsagittal line and the palatal suture can be used as a midsagittal basal reference line.

The null hypotheses are: The line between external auditory meatus is not perpendicular to skull midsagittal line. The palatal suture (lat. *sutura palatina mediana*) is not adequate with the midsagittal plane.

## MATERIAL AND METHODS

62 human skulls (26 female and 36 male) were randomly taken from osteological collection of the Department of Anatomy, Histology and Anthropology (Vilnius University, Medicine faculty). All the skulls belonged to one archaeological sample from Alytus (Lithuania). Sex of individuals was estimated according to pelvic bones of skeletons.

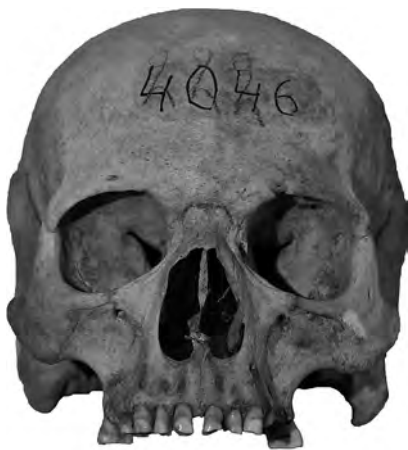

Fig. 3. Frontal view

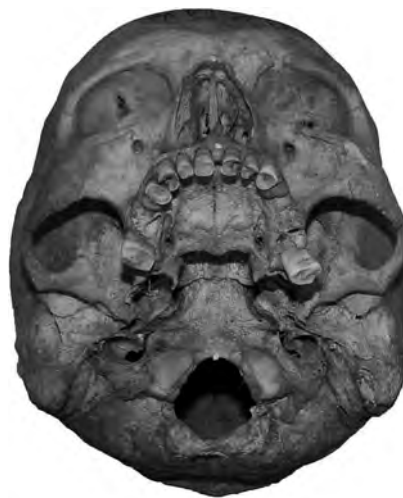

Fig. 4. Frontobasal view

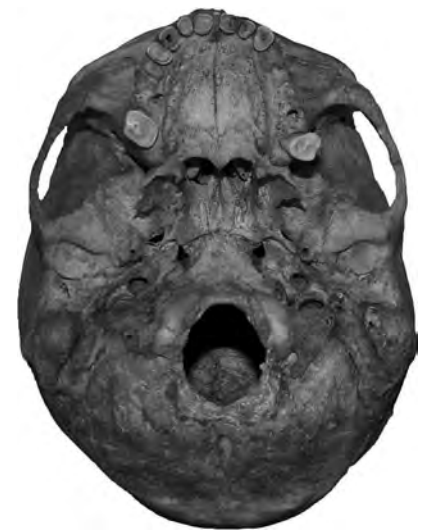

Fig. 5. Basal view

Skulls inclusion criteria were:

1. Age above 20 years (age determination was approved according to the ossification of the skull sutures);
2. Skulls without distortions;
3. Clearly visible external auditory meatus (lat. *meatus acusticus externus*), palatal suture (lat. *sutura palatina mediana*), craniometrical landmarks:
  - a. *Basion* – The most inferior point on the anterior margin of foramen magnum, at base of clivus in frontal view or midsagittal point on the anterior margin of the foramen magnum in basal view;
  - b. *Prosthion* – The most inferior point of maxilla between central incisors in frontal view or the most ventral point of maxilla in basal view;
  - c. *Nasion* – Midsagittal point at junction of frontal and nasal bones at nasofrontal suture.

The skulls were placed in a skull holder in a stable position. Camera (Nikon 40 D and 50 mm Nikkor lens) was positioned on a tripod (90° in a surface) in a fixed location. The standard angles of taking photos were chosen as follows:

1. 90 degrees to the frontal view of the skull (Fig. 3);
2. 45 degrees to the basal – frontal view of the skull (Fig. 4);
3. 90 degrees to the basal view of the skull (Fig. 5).

Analysis of the images continued with Adobe Photoshop CS5 measurement tool (Adobe, USA). The line was drawn over a region of petrous part of temporal bone connecting the frontal points of both external auditory meatus and the angle to the

midsagittal plane (Fig. 6) was measured in basal and frontobasal skull views (further – The angle). Another line extending from palatal suture in frontal and distal directions was evaluated for the adequacy with the median sagittal skull plane in basal and frontobasal images.

Two independent observers analysed the photos.

Statistical analysis was performed by SPSS 17 (IBM) included descriptive statistics, Kolmogorov–Smirnov test, t-test and ANOVA.

## RESULTS

There were 62 skulls (26 female and 36 male) in 4 age groups (Table 1).

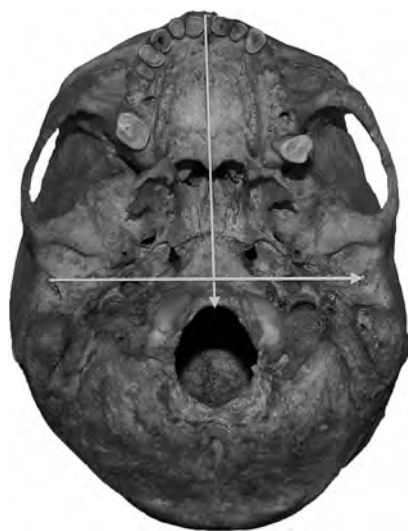Inter-observer agreement of two researchers for quantitative data was evaluated with Pearson Correlation: ranging R from 0.94 to 0.95 in different pictures measurements (meaning a strong relationship) (Fig. 7).

The distribution of the angles was normal (Kolmogorov–Smirnov test,  $p > 0.05$ ).

The mean value for angle in basal views was 90.12° (SD=1.48°) and in frontobasal 90.36° (SD=2.25°). The mean value for angle difference from right angle in basal views was -0.12° (SD=1.48°) (Fig. 8) and in frontobasal views -0.36° (SD=2.25°). The

**Table 1.** Distribution according the age and sex

Age, years	Male		Female		Total	
	N	%	N	%	N	%
20-30	4	11.1	8	30.8	12	19.4
30-40	8	22.2	5	19.2	13	20.9
40-50	15	41.7	6	23.1	21	33.9
>50	9	25.0	7	26.9	16	25.8
All	36	100.0	26	100.0	62	100.0



**Fig. 6.** Measurements of the angles in basal views

mean value for absolute angle difference in basal views was 1.17° (SD=0.9°) (Fig. 9) and in frontobasal views 1.69° (SD=1.5°).

There was no statistically significant difference of means in the age and sex groups (Table 2, 3).

Analysing the adequacy of palatal suture to the median sagittal plane in basal and frontobasal images followed 4 evaluation groups: suture is adequate with the midsagittal plane, it is likely to be adequate, it is parallel and it is not adequate to the midsagittal plane (Table 3) (this assessment was suggested by the authors).

Inter-rater Kohen's Kappa Coefficient was 0.702 ( $p < 0.05$ ) meaning a high inter-rater agreement for qualitative data (Table 4).

**DISCUSSION**

This study has several limitations, which must be taken into consideration.

Firstly, the methodology of photographing the skulls is not accurate because of possible changes in skull placement tridimensionally. Using computerized methods (22) or skull-adapting positioning devices (32) are more specific. Method of taking photos was chosen this time because of easy technical accessibility and opportunities of evaluation for the pilot study. Further study should be made measuring the angles more precisely in computer tomograms (33-36).

Secondly, the photos were taken of XVII<sup>th</sup> century dry human skulls, which may have been damaged during excavation or storage, despite no external signs of injury were visible. Furthermore, dry skulls, which had the biggest values of asymmetry, were noticed to

**Table 2.** Descriptive statistics for measured angles in basal and frontobasal views for genders

View	Gender	N	Measurements in degrees, °											
			Mean	SD	Min	Max	Abs. Angle Difference	SD	Min	Max	Angle Difference	SD	Min	Max
Basal	Female	26	90.32	1.48	88.10	93.40	1.23	0.84	0.10	3.40	0.32	1.48	-1.90	3.40
	Male	36	89.98	1.49	86.19	93.90	1.13	0.95	0.00	3.90	-0.02	1.49	-3.10	3.90
	Total	62	90.12	1.48	86.90	93.90	1.17	0.90	0.00	3.90	0.12	1.48	-3.10	3.90
Frontobasal	Female	26	90.61	1.60	87.30	93.70	1.32	1.06	0.10	3.70	0.61	1.60	-2.70	3.70
	Male	36	90.18	2.62	84.10	95.20	1.96	1.72	0.00	5.90	0.18	2.62	-5.90	5.20
	Total	62	90.36	2.25	84.10	95.20	1.69	1.50	0.00	5.90	0.36	2.25	-5.90	5.20

**Table 3.** Descriptive statistics for measured angles in basal and frontobasal views for all age groups

View	Age	N	Measurements in degrees, °											
			Mean	SD	Min	Max	Abs. Angle Difference	SD	Min	Max	Angle Difference	SD	Min	Max
Basal	20-30	12	90.26	1.41	87.80	92.70	1.04	0.94	0.10	2.70	0.26	1.41	-2.22	2.70
	30-40	13	90.37	1.57	88.20	93.90	1.23	0.98	0.00	3.90	0.37	1.57	-1.80	3.90
	40-50	21	90.02	1.33	87.80	93.10	1.04	0.80	0.10	3.10	0.02	1.33	-2.20	3.10
	>50	16	89.96	1.74	86.90	93.40	1.40	0.97	0.10	3.40	-0.04	1.74	-3.10	3.40
	Total	62	90.12	1.48	86.90	93.90	1.17	0.90	0.00	3.90	0.12	1.48	-3.10	3.90
Frontobasal	20-30	12	90.16	1.61	87.70	92.20	1.39	0.71	0.20	2.30	0.16	1.61	-2.30	2.20
	30-40	13	90.68	2.31	87.30	95.20	1.72	1.63	0.10	5.20	0.68	2.31	-2.70	5.20
	40-50	21	90.10	2.58	84.10	94.10	1.88	1.71	0.00	5.90	0.10	2.58	-5.90	4.10
	>50	16	90.58	2.29	85.70	95.00	1.66	1.64	0.10	5.00	0.58	2.29	-4.30	5.00
	Total	62	90.36	2.25	84.10	95.20	1.69	1.50	0.00	5.90	0.36	2.25	-5.90	5.20

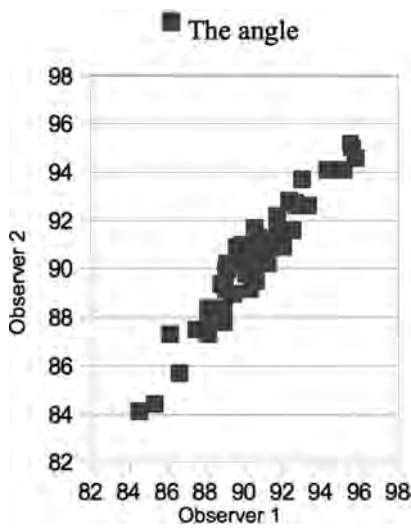


Fig. 7. Inter-observer correlation

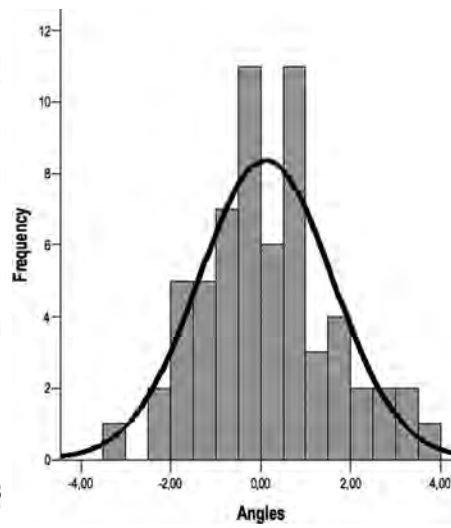


Fig. 8. Distributions of angle differences in basal views

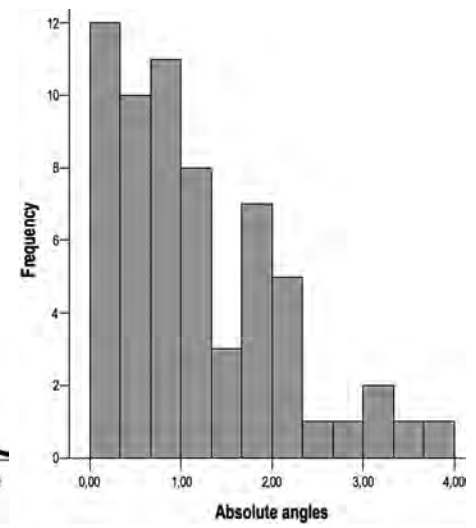


Fig. 9. Distributions of absolute angle differences in basal views

have other skull asymmetries (e.g. different length of zygomatic arch), that may hint about plagiocephaly. The prevalence of plagiocephaly is reported to be from 3.3% (in children) (39) to 1% (in teenagers) (37), but rising after „Back to sleep campaign“ in 1992 (38, 40, 41). The prevalence of asymmetry in contemporary skulls may be even higher.

Thirdly, finding the reference points on dry skulls in the images is not always simple because of similar colours or over covering anatomical sights. The main points of midsagittal plane were always visible but the problem appeared in exactly locating the edge of external auditory meatus and finding the most frontal point, because meatus is not a point, but an area in the image. The inter-rated agreement (Cohen's Kappa 0.702,  $p < 0.05$ ) and Pearson correlation coefficient (0.95,  $p < 0.05$ ) were high, supporting the precision of measuring under the limits of the study.

Facebow's terminal parts (olivas) are positioned into the external auditory meatus and rest on the soft tissues of the head, which do not exactly correspond the underlying hard tissues. Soft tissues may equalize the asymmetry of the external auditory meatus or enhance the present bony asymmetry.

There are no studies yet analysing the symmetry of external auditory meatus in horizontal plane to the midsagittal plane. The mean of these angle differences

in basal views are  $90.12^\circ$  ( $SD=1.48^\circ$ ) with normal data distribution indicating a fluctuating asymmetry in human skulls. Only two studies by Rodrigues *et al.* (23, 24) analysed this kind of symmetry measuring the angles and distances between condyles and median sagittal plane. They found difference between left and right sides' distances only in Angle class II division 1. Condyles are parts of the mandible and can not be accurately compared to the symmetry of the external auditory meatus.

The results of adequacy of palatal suture (lat. *sutura palatina mediana*) to the midsagittal plane do not disagree with the results of de Araujo *et al.* (28). They found that maxillary and mandibular dental midlines, palatal suture on the casts and median sagittal plane on the radiographs were almost coincident. Analysing the images in this study revealed the possible forms of this suture (starting from incisal canal and extending to posterior nasal spine): straight, forms of „S“ or „C“ letters, wide or narrow suture. In about 90% measured cases the ends of the line or the biggest parts of the suture could be coincident with the midsagittal plane, but the evaluation was not easy. De Araujo *et al.* analysed 20 individuals with normal occlusion in average 22.4 years old and our study did not regard normal occlusion and had a wider range of age groups.

Further investigation on clinical significance of these asymmetries in restorative dentistry and orthodontics is needed.

## CONCLUSIONS

Considering the limits of this study the angle between external auditory meatus and midsagittal skull plane has a characteristic fluctuating asymmetry.

Table 4. Distribution according the age and sex

	Basal		Frontobasal			
	N	%	%	N	%	%
Adequate	73	58.9		35	28.2	
Likely adequate	23	18.5	90.3	46	37.1	85.5
Parallel	16	12.9		25	20.2	
Not adequate	12	9.7	9.7	18	14.5	14.5

The congruence of *suture palatina mediana* and midsagittal plane is debatable.

### CLINICAL RELEVANCE

Using facebow for every patient's mouth rehabilitation should be evaluated carefully because of a possible errors occurring due to asymmetry of the human skulls. Alternative using of palatal suture as

one of the reference lines needs more precise measurements on computer tomograms.

### ACKNOWLEDGEMENTS

We would like to thank Vilnius University, Medicine faculty, Department of Anatomy, Histology and Anthropology for a possibility to use the osteological collection of the skulls.

### REFERENCES

1. Malafaia FM, Garbossa MF, Neves AC, DA Silva-Concilio LR, Neisser MP. Concurrence between interpupillary line and tangent to the incisal edge of the upper central incisor teeth. *J Esthet Restor Dent* 2009;21:318-22.
2. Eskelsen E, Fernandes CB, Pelogia F, Cunha LG, Pallos D, Neisser MP, Liporoni PC. Concurrence between the maxillary midline and bisector to the interpupillary line. *Esthet Restor Dent* 2009;21:37-41.
3. Al Quran FA, Hazza'a A, Al Nahass N. The position of the occlusal plane in natural and artificial dentitions as related to other craniofacial planes. *J Prosthodont* 2010;19:601-5.
4. Kato T. A study on the reference planes and lines for dental practice. *Aichi Gakuin Daigaku Shigakkai Shi* 1990;28(1 Pt 1):1-19.
5. Hofmann M. The so-called "Camper's" plane as a reference plane for the construction of artificial sets of teeth. *Dtsch Zahnarztl Z* 1979;34:606-8.
6. The academy of Prosthodontic. The glossary of prosthodontic terms. 8<sup>th</sup> ed (GPT-8). *J Prosthet Dent* 2005;94:1-92.
7. Morneburg TR, Pröschel PA. Impact of arbitrary and mean transfer of dental casts to the articulator on centric occlusal errors. *Clin Oral Investig* 2011;15:427-34.
8. Morneburg TR, Pröschel PA. Predicted incidence of occlusal errors in centric closing around arbitrary axes. *Int J Prosthodont* 2002;15:358-64.
9. Piehslinger E, Bauer W, Schmiedmayer HB. Computer simulation of occlusal discrepancies resulting from different mounting techniques. *J Prosthet Dent* 1995;74:279-83.
10. Pröschel PA, Maul T, Morneburg T. Predicted incidence of excursive occlusal errors in common modes of articulator adjustment. *Int J Prosthodont* 2000;13:303-10.
11. Palik JF, Nelson DR, White JT. Accuracy of an earpiece face-bow. *J Prosthet Dent* 1985;53:800-4.
12. Ferrario VF, Sforza C, Miani A Jr, Serrao G. A three-dimensional evaluation of human facial asymmetry. *J Anat* 1995;186(Pt 1):103-10.
13. Ferrario VF, Sforza C, Ciusa V, Dellavia C, Tartaglia GM. The effect of sex and age on facial asymmetry in healthy subjects: a cross-sectional study from adolescence to mid-adulthood. *J Oral Maxillofac Surg* 2001;59:382-8.
14. Djordjevic J, Pirttiniemi P, Harila V, Heikkinen T, Toma AM, Zhurov AI, Richmond S. Three-dimensional longitudinal assessment of facial symmetry in adolescents. *Eur J Orthod* 2013;35:143-51.
15. Djordjevic J, Toma AM, Zhurov AI, Richmond S. Three-dimensional quantification of facial symmetry in adolescents using laser surface scanning. *Eur J Orthod* 2014;36:125-32.
16. An SV. [The intergroup variability of the indices of asymmetry of the human facial skull]. *Morfologija* 1993;104:112-23. Rus.
17. Kolesnikov LL, An SV. [Asymmetry of the facial skeleton in Negroid skulls]. *Stomatologija (Mosk)*. 1999;78:39-41. Rus.
18. Kadanoff D, Jordanov J. Asymmetry in the structure of the middle part of the facial skull. *Gegenbaurs Morphol Jahrb* 1978;124:305-21.
19. Ferrario VF, Sforza C, Poggio CE, Tartaglia G. Distance from symmetry: a three-dimensional evaluation of facial asymmetry. *J Oral Maxillofac Surg* 1994;52:1126-32.
20. Peck H, Peck S. A concept to facial esthetics. *Angle Orthod* 1970;40:284-318.
21. Schöttl R, Plaster U. Modelübertragung und Kommunikation zwischen Zahnarzt und Zahntechniker. *Quintessenz Zahntech* 2010;36:528-43.
22. Zadurska M, Sandham JA, Wohlgemuth B. The use of a computer to measure linear and angular variables for an assessment of symmetry of the base of the skull. *Czas Stomatol* 1990;43:348-56.
23. Rodrigues AF, Fraga MR, Vitral RW. Computed tomography evaluation of the temporomandibular joint in Class II Division 1 and Class III malocclusion patients: condylar symmetry and condyle-fossa relationship. *Am J Orthod Dentofacial Orthop* 2009;136:199-206.
24. Rodrigues AF, Fraga MR, Vitral RW. Computed tomography evaluation of the temporomandibular joint in Class I malocclusion patients: condylar symmetry and condyle-fossa relationship. *Am J Orthod Dentofacial Orthop* 2009;136:192-8.
25. Katsavrias EG, Dibbets JM. The postglenoid tubercle: prevalence and growth. *Ann Anat* 2002;184:185-8.
26. Jasinevicius TR, Pyle MA, Lalumandier JA, Nelson S, Kohrs KJ, Türp JC, Sawyer DR. Asymmetry of the articular eminence in dentate and partially edentulous populations. *Cranio* 2006;24:85-94.
27. Todd NW. Tympanum-canal angles anteriorly, anteroinferiorly, and inferiorly: a postmortem study of 41 adult crania. *Ear Nose Throat J* 2009;88:E22-7.
28. de Araujo TM, Wilhelm RS, Almeida MA. Skeletal and dental arch asymmetries in individuals with normal dental occlusions. *Int J Adult Orthodon Orthognath Surg*;1994;9:111-8.
29. Ferrario VF, Sforza C, Colombo A, Tartaglia GM, Carvajal R, Palomino H. The effect of ethnicity and age on palatal size and shape: a study in a northern Chilean healthy population. *Int J Adult Orthodon Orthognath Surg* 2001;15:233-40.
30. Bookstein FL, Gunz P, Mitteroecker P, Prossinger H, Schaefer K, Seidler H. Cranial integration in Homo: singular warps analysis of the midsagittal plane in ontogeny and evolution. *J Hum Evol* 2003;44:167-87.
31. Moshiri M, Scarfe WC, Hilgers ML, Scheetz JP, Silveira AM, Farman AG. Accuracy of linear measurements from imaging plate and lateral cephalometric images derived from cone-beam computed tomography. *Am J Orthod Dentofacial Orthop* 2007;132:550-60.
32. Smith P, Walker G. On techniques for stabilising and photographing skulls. *Am J Phys Anthropol* 1977;46:167-9.
33. Li H, Xie Z, Ruan S, Wang H. The measurement and

- analyses of symmetry characteristic of human skull based on CT images. *Sheng Wu Yi Xue Gong Cheng Xue Za Zh.* 2009;26:34-7.
34. You KH, Lee KJ, Lee SH, Baik HS. Three-dimensional computed tomography analysis of mandibular morphology in patients with facial asymmetry and mandibular prognathism. *Am J Orthod Dentofacial Orthop* 2010;138:540.e1-8.
  35. Sanders DA, Rigali PH, Neace WP, Uribe F, Nanda R. Skeletal and dental asymmetries in Class II subdivision malocclusions using cone-beam computed tomography. *Am J Orthod Dentofacial Orthop* 2010;138:542.e1-20.
  36. Kwon TG, Park HS, Ryoo HM, Lee SH. A comparison of craniofacial morphology in patients with and without facial asymmetry--a three-dimensional analysis with computed tomography. *Int J Oral Maxillofac Surg* 2006;35:43-8.
  37. Roby BB, Finkelstein M, Tibesar RJ, Sidman JD. Prevalence of positional plagiocephaly in teens born after the "Back to Sleep" campaign. *Otolaryngol Head Neck Surg* 2012;146:823-8.
  38. Turk AE, McCarthy JG, Thorne CH, Wisoff JH. The "back to sleep campaign" and deformational plagiocephaly: is there cause for concern? *J Craniofac Surg* 1996;7:12-8.
  39. Bialocerkowski AE, Vladusic SL, Wei Ng C. Prevalence, risk factors, and natural history of positional plagiocephaly: a systematic review. *Dev Med Child Neurol* 2008;50:577-86.
  40. Pogliani L, Mameli C, Fabiano V, Zuccotti GV. Positional plagiocephaly: what the pediatrician needs to know. A review. *Childs Nerv Syst* 2011;27:1867-76.
  41. Losee JE, Mason AC. Deformational plagiocephaly: diagnosis, prevention, and treatment. *Clin Plast Surg* 2005;32:53-64
  42. Wong TY, Liu JK, Fang JJ, Wu TC, Tu YH. Use of the matching optimal symmetry plane method in planning surgical correction of facial asymmetry--a preliminary report of 20 patients. *aJ Oral MaxillofacSurg* 2014;72:1180.e1-1

Received: 04 03 2013

Accepted for publishing: 26 09 2014