

An unusual complication of genioglossus advancement surgery

Metin Sencimen, Aydin Gülses, Gurkan Rasit Bayar, Timur Akcam

SUMMARY

Objective. Genioglossus advancement is a surgical procedure where the base of the tongue is pulled forward, usually to increase airway size due to deformity or a sleep breathing disorder. In this procedure, a small bony window is made in the lower jaw. The piece of bone along with the attachment for the tongue is pulled forward and down, then fastened to the outside of the lower jaw. Here we report a 43 year old male patient which has admitted to our department with the complaints of the mild pain and swelling on the chin area.

Material and Methods. The patient underwent a genioglossus advancement surgery 3 months ago. An ortopantomograph revealed a root fracture of the lower left canine. Under mandibular nerve block, the lower left canine was extracted and the root piece was removed via an endodontic K-file.

Results. The healing period was uneventfull and no signs or symptoms of a pathology was detected.

Conclusion. Dental complications related to genioglossus advancement are rarely reported. However, the surgeons should be aware of damage the roots of the adjacent teeth, especially the lower canines.

Keywords: dental trauma; genioglossus advancement; obstructive sleep apnea.

INTRODUCTION

Several studies have demonstrated that the mandible and the tongue are major determinants of the airway dimension. Anterior positioning of these structures has been shown to improve obstructive sleep apnea (OSA). The genioglossus advancement (GA) procedure which was first described by Riley et al in 1993 (1), enlarges the retrolingual airway by anterior advancement of the genioide tubercle of the mandible through a limited parasagittal mandibular osteotomy and anterior advancement of the tongue (2). The procedure consists of a rectangular window of symphyseal bone consisting of the geniotubercle. The rectangle is advanced anteriorly, rotated to allow bony overlap, and immobilized with a titanium screw. The advanced bone places tension on the tongue musculature and thus limits the posterior displacement during sleep.

In general, the potential risks associated with GA are quite limited, including infection, hematoma, injury to the genioglossus muscle, and paresthesia of the lower teeth (3). The aim of this paper is to report a root fracture as an unusual complication of genioglossus advancement surgery.

CASE REPORT

A 43 year old male patient has admitted to the Department of Oral and Maxillofacial Surgery at Gulhane Military Medical Academy (GMMA) with the complaint of pain on the left parasymphiseal region. According to the patients' history, he underwent a GA surgery performed at a local hospital by an ear,nose and throat consultant 3 months ago for the treatment of OSA . Extraoral and intraoral examinations revealed no signs of a pathology, however, the lower left canine was tender to percussion. A panoramic radiograph revealed a fracture in the lower third of the root of the lower left canine, adjacent to the bony window created for GA surgery (Figure). A consultation was made with the Department of Otolaryngology at GMMA, and because of the possible risk of infection following the endodontic treatment and endodontic surgery,

¹Gülhane Military Medical Academy Department of Oral and Maxillofacial Surgery, Etlik Ankara, Turkey

²Ankara Medical Park Hospital, Department of Otorhinolaryngology, Ankara Turkey

Metin Sencimen¹ – D.D.S., PhD

Aydin Gülses¹ – D.D.S., PhD

Gurkan Rasit Bayar¹ – D.D.S., PhD

Timur Akcam² – M.D., PhD

Address correspondence to Aydin Gülses, Ankara Mevki Military Hospital, 06130 Diskapi Ankara, Turkey.

E-mail address: aydingulses@gmail.com

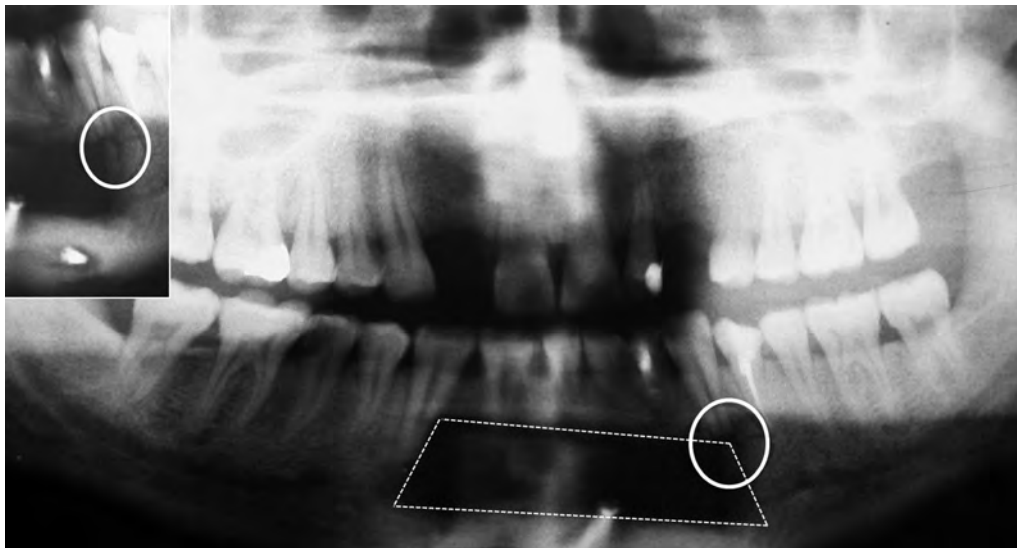


Fig. The fracture in the lower third of the root of the lower left canine (white circle) adjacent to the bony window (white dots) created for GA surgery

it was decided to extract the lower left canine. An informed consent was obtained, the lower left canine was extracted under mandibular nerve block. The root piece was removed via an endodontic K-file. The healing period was uneventful and no signs or symptoms of a pathology was detected.

DISCUSSION

Complications related to GA are rarely reported. Labiogingival incision dehiscence, lower lip paresthesia, anterior mandibular infection, mandible fracture, tongue/floor of mouth hematoma, dental paresthesia, postoperative upper air way obstruction are the possible complications of GA surgery. Riley *et al.* (4) listed the following complications in GA: infection (<1%), permanent anesthesia (<6%), and seroma (<2%). According to Mickelson (5), a list of potential complications of GA surgery centers on performance of the surgical technique and perioperative precautions would reduce the incidence of these complications.

It has been suggested that, a panoramic radiograph could rule out any significant anterior man-

dibular bone or dental complications (5). In addition, the identification of the geniotubercle on a panoramic radiograph and digital palpation of the floor of the mouth could allow the surgeon to estimate the height of the genioglossus muscle insertion and reduce the risk of amputating dental roots and mandible fracture from weakening of the

In order to prevent the roots adjacent to the bony window, Mickelson *et al* proclaimed that the inferior osteotomy should be no less than 6 mm from the inferior mandibular border, the superior osteotomy an estimated 5 mm inferior to the dental incisor root apices, and the vertical osteotomies immediately medial to the canine roots (5).

Riley *et al.* (1) stated that, pathologic mandibular fracture can occur when the osteotomy violates the inferior border of the mandible or induces lesions or infections of the roots of the teeth (4). A postoperative infection adjacent to the repositioned fragment during GA surgery could also result in the loss of the fragment and complicate the outcomes of the OSA surgery. In the current case, we think that the elimination of the risk of an infection was essential and therefore we decided to extract the tooth.

Dental complications related to GA are rarely reported. However, the surgeons, especially otolaryngologists, should be aware of damage the roots of the adjacent teeth, especially the lower canines.

The authors of the current manuscript declare that they have no conflict of interest.

REFERENCES

1. Riley RW, Powell NB, Guilleminault C. Obstructive sleep apnea syndrome: a review of 306 consecutively treated surgical patients. *Otolaryngol Head Neck Surg* 1993;108:117-25.
2. Guilleminault C, Abad VC. Obstructive sleep apnea. *Curr Treat Options Neurol* 2004;6:309-17.
3. Li KK. Surgical therapy for obstructive sleep apnea syndrome. *Semin Respir Crit Care Med* 2005;26:80-8.
4. Riley R, Powell N, Li K, Guilleminault C. Surgical therapy for obstructive sleep apnea-hypopnea syndrome. In: *Principles and practice of sleep medicine*. Kryger M, Roth T, Dement W., eds. 3rd ed. Philadelphia: WB Saunders Company; 2000. p. 913-28.
5. Mickelson SA. Lower pharyngeal airway surgery. In: *Snoring and obstructive sleep apnea*. Fairbanks DNF, Mickelson SA, Woodson BT. eds. 3rd ed. New York: Lippincott Williams & Wilkins Company; 2003. p. 176-77.

Received: 13 03 2012
Accepted for publishing: 28 12 2015