

Evaluation of the posterior maxillary teeth movements during Class II correction: 3-dimensional superimposition of casts

Igor Griblasky¹, Dalia Latkauskiene², Gundega Jakobsone¹

SUMMARY

Aim and objectives. The aim of this study was to analyze the changes of the posterior dentition during Class II correction with the crown Herbst appliance (cHerbst) and intermaxillary Class II elastics.

Sample. Class II patients were divided into 2 groups: those who were treated with the cHerbst appliances (n=40, mean age 14.1±1.3) and those who were treated with fixed appliances and Class II elastics (n = 20, mean age 16.7±2.7).

Materials and methods. The scans of pre- and post-treatment casts the patients were superimposed and registered using the freeware Blender 2.67. The linear measurements in the anteroposterior, transversal and vertical planes along with the rotation angles of the first molars were assessed.

Results. In the cHerbst group clinically significant derotation (13.8±5.0°) and distalization (3.2±1.2 mm) of the upper first molars were recorded compared to the intermaxillary Class II elastics group (4.2±5.5°, -0.3±1.5, respectively). In the cHerbst group the second and first premolars followed the distal movements of the upper first molars. The premolars expanded slightly more than the molars in both groups. The posterior teeth extruded in both groups, except the molars in the cHerbst group.

Conclusions. The crown Herbst appliance is significantly more effective in molar derotation and distalization than intermaxillary Class II elastics.

Key words: Class II treatment, Class II elastics, Herbst appliance, cast scans.

INTRODUCTION

During the last decades a wide range of fixed and removable functional appliances have been developed for correction of Class II malocclusion. A current trend in Class II management has shifted towards non-extraction treatment and fixed functional appliance usage (1). In 1979 Panherz (2) reintroduced the Herbst appliance, which was considered to require less compliance. The main disadvantages of the traditional Herbst appliance were the high production costs and breakage rates (3). Therefore, Class II elastics remained as the most used treatment modality for Class II correction.

The effects of the Herbst appliance have been published extensively in the literature (4-11). The

distal movement of the upper molars has shown to have a significant contribution in the molar relationship correction (4, 5, 8), especially in adults (6, 7) when treating with the Herbst appliance. On the contrary, the cephalometric studies suggest that Class II elastics in conjunction with fixed appliances do not distalize the upper molars (11-14). However, some derotation due to the molar tube prescription might be expected.

A few studies on the treatment effects of the Herbst appliance has been performed on the dental casts (9, 15-17). The digital models have a capacity to offer a quantifiable, directional, accurate and reliable way of assessing dental change without exposure to radiation provided that they are superimposed and registered in space (18, 19). In a previous study, the method based on the surface to surface matching technology using the palate as reference area for superimposition of 3D digital casts was demonstrated to be clinically as reliable as cephalometric superimposition for assessing ortho-

¹Department of Orthodontics, Institute of Stomatology, Riga Stradins University, Riga, Latvia

²Private practice, Kaunas, Lithuania

Correspondence to: Gundega Jakobsone, Department of Orthodontics, Institute of Stomatology, Riga Stradins University, Dzirciema street 20, Riga LV 1007, Latvia.
E-mail address: g.jakobsone@latnet.lv

dontic tooth movements (19). Unfortunately, the same stable reference for the mandible is not available if a patient has not a mandibular torus (20).

The aim of the present study was to evaluate the immediate effects of the crown Herbst appliance and the Class II elastics on the posterior dentition using 3D model superimposition.

MATERIALS AND METHODS

This study was approved by the Ethics in Research Committee of the Riga Stradins University. In the study were included all consecutive patients from the private clinic by one of the authors (D. L.) and who had at least half cusp Class II molar relationship and started treatment from February 2012 to October 2012. The crown Herbst appliance (Figure 1) was placed in 42 individuals. Later 2 individuals were excluded from the study sample due to dental impactions and underwent surgical intervention. The final study sample (cHerbst group) consisted of 23 girls and 17 boys with the mean age of 14.1 ± 1.3 years, ranging from 11.9 to 16.9 years. The design and clinical management of the appliance has been described before (21). In cases of Class II division 2 (n=25) fixed appliances were placed to convert division 2 into division 1. Class I or overcorrected Class I relationship was achieved in all cases. Duration of the functional treatment was 11.7 ± 1.2 months.

In the Class II elastics group were included 20 individuals (6 males/14 females) who refused to have the Herbst appliance due to several reasons and who's treatment was started

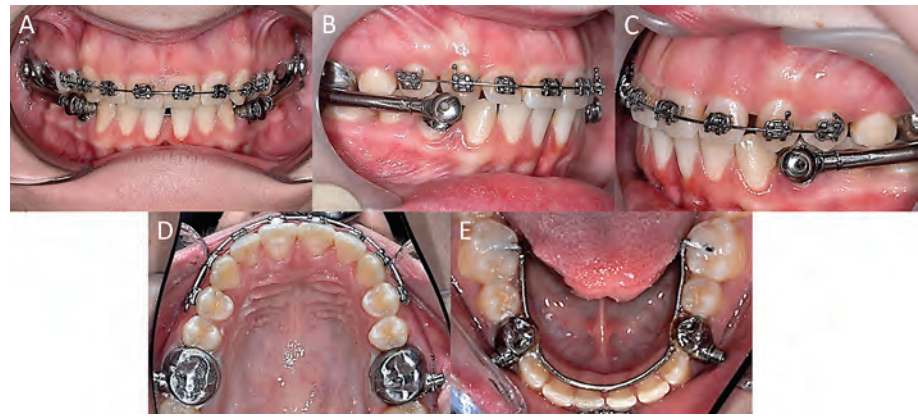


Fig. 1. The crown Herbst appliance

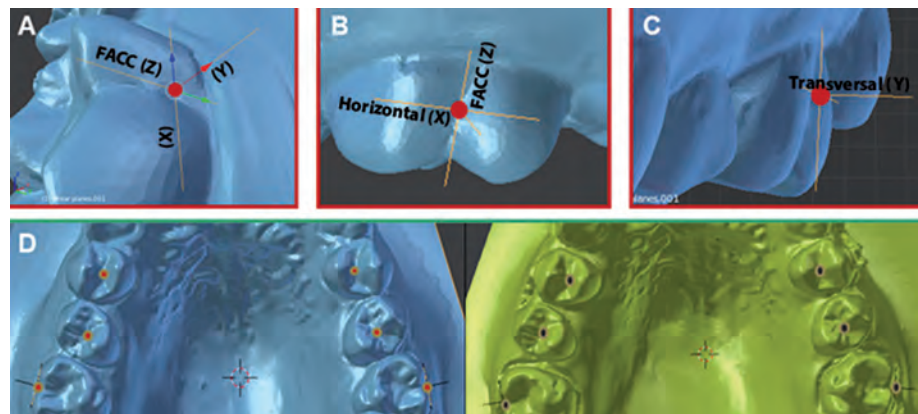


Fig. 2. Molar and premolar landmarks. A – facial axis (FA) point of the molar and corresponding axes (X, Y, Z). B – facial axis of the clinical crown (FACC or Z axis) and X axis of the molar. C – frontal cross-sectional view showing the Y axis of the molar. D – occlusal views of the premolar and molar points on the pre-treatment (blue) and post-treatment (green) casts.




Fig. 3. Digitization of the medial rugae on each cast

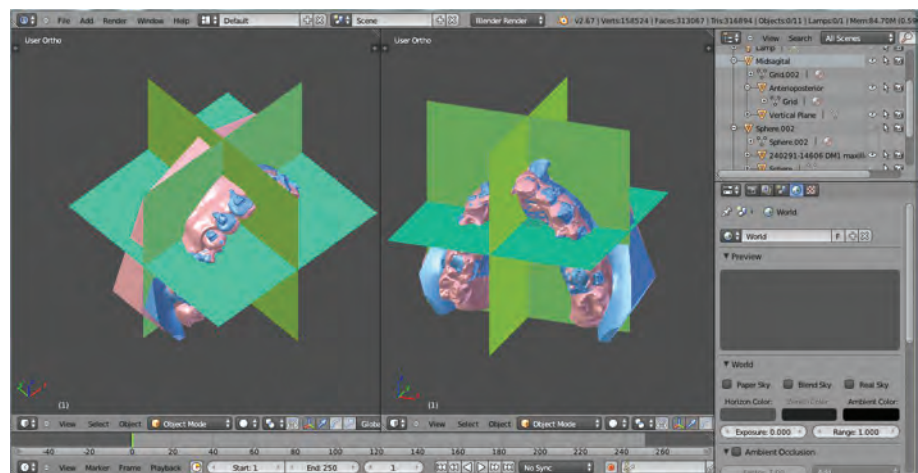


Fig. 4. Assignment of the cast planes

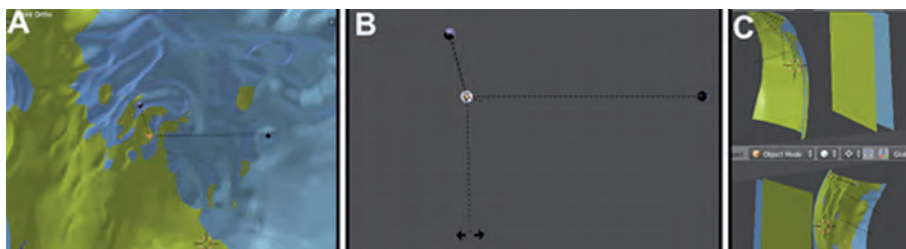


Fig. 5. The superimposition process. A – the points of the pre-treatment cast are moved together with its registered cast to align with the points of the post-treatment cast and its registered cast. B – points are aligned together rotationally in all 3 planes, until the best fit among all corresponding points is achieved. Because the points are registered to the casts, any movement or rotation of these points move or rotate the cast. C – the posterior palatal vault region (minimum area 5×5 mm) is used to correct and/or confirm the palatal inclination and height discrepancies.

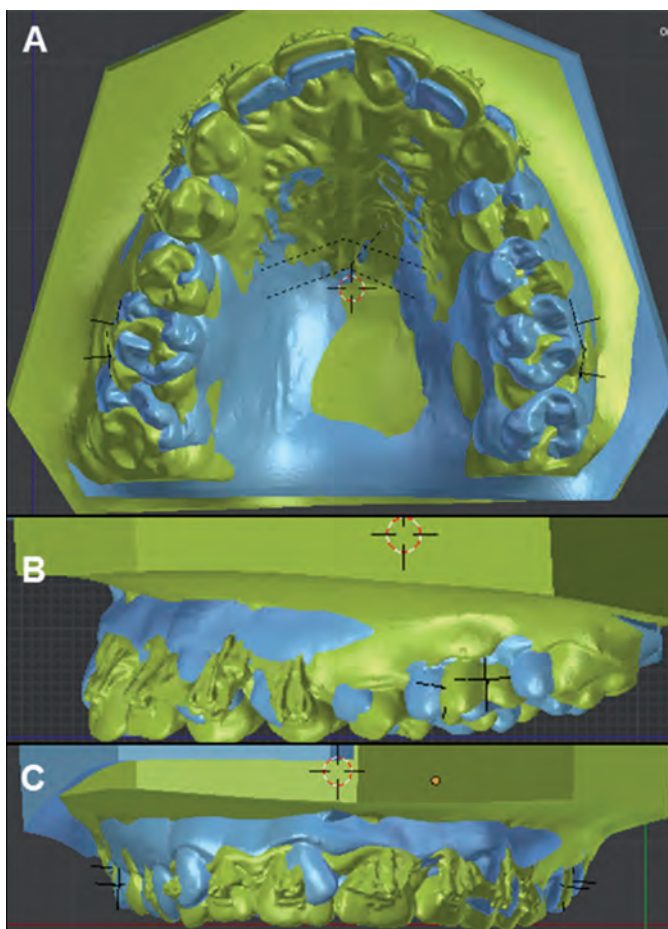


Fig. 6. Final superimpositions. A – occlusal view. B – sagittal view. C – frontal view. The cursor is situated at the same place in all views.

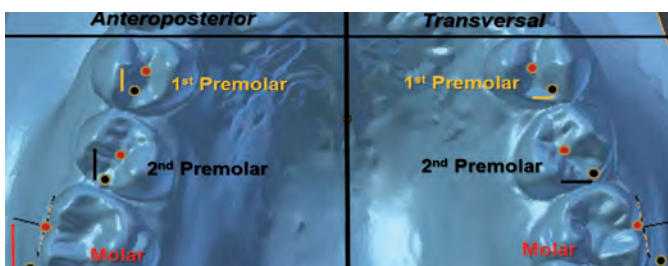


Fig. 7. Graphical presentation of the measurements between the reference points of each cast set in the anteroposterior and transversal planes. Red dots represent the reference points on the pre-treatment casts and the black dots represent the reference points on the post-treatment casts.

at the same time. In the Class II elastics group the mean age was 16.7 ± 2.7 years, ranging from 13.4 to 22 years. In this group 0.022 slot brackets with 7° distal offset for the 1st molar tubes were used. The Class II elastics (4 ½ oz. or 6 oz.) were prescribed for the full-time wear when the 0.019 \times 0.025-inch stainless steel arch wire was inserted in the upper arch. The mean treatment time with the

elastics was 9.5 ± 3.6 months and the total treatment time was 25.6 ± 4.0 months. Sixty sets of pre- and post-treatment casts were scanned with the 3Shape R700™ Scanner using the ScanItOrthodontics™ application (3Shape, Copenhagen, Denmark). The cast superimpositions and measurements were done by the first author (I.G) using a freeware Blender 2.67 (Blender Foundation, Amsterdam, Netherlands).

The superimposition technique was as follows:

1. Digitization/registration of points: Two different sets of points were assigned: the measurement points and the registration points. The measurement points were: the molar facial axis (FA) points as described by Andrews (22) and the premolar groove points. The molar planes were placed according to the facial axis of the clinical crown (FACC) along the buccal groove while straddling the buccal surface (Figure 2A-C). The use of FACC for superimposition procedures of 3D models was previously proposed by Cho *et al.* (23) The premolar points were the deepest mid-points in the groove between the buccal and lingual cusps (Figure 2D). The registration points were 3 points along the medial part of the third rugae which were registered on each cast separately (Figure 3).
2. Assignment of the cast planes. First, the midsagittal plane was defined by a line crossing through mid-palatine raphe and incisive papilla. The anteroposterior and the vertical/horizontal planes were then dropped perpendicularly to the midsagittal plane. All the planes intersect in the mid-point of the digitized medial rugae points (Figure 4).
3. Superimposition: the registered medial rugae points were brought together and aligned in all planes to overlap each other (Figure 5A, B). Finally, a stable mid-palatine surface

area (19) was used to confirm or correct the alignment of both casts (Figure 5C).

With the completion of the superimposition (Figure 6) the scans were registered. The linear measurements were obtained as the distances from the measurement points to the cast planes (Figure 7). The angular measurements were calculated between the molar planes and cast planes.

Statistical analysis

The samples were tested for the normality of distribution by the means of Shapiro-Wilk test. As the samples revealed normal distribution, parametric statistical tests (independent t-test and Pearson's correlation) were performed.

Post-hoc power calculation was performed for two independent samples based on the sample sizes and the mean change of the distal movement of the molars in the cHerbst and Class II elastics groups. The power was 100 percent at an alpha level of 0.05.

Method error

In order to check the reliability of the superimposition technique, 20 of the 60 sets of casts were chosen randomly, re-superimposed and re-measured after at least 2 weeks. Dahlberg's calculation and Houston's estimate of systematic error were computed to detect random and systematic errors, respectively, for the reference points' identification. The random error ranged from 0.03 mm for the intermolar width to 0.85 mm for the upper first molar distance to the 3rd rugae perpendicular. No systematic error was detected. The reliability of the superimposition technique and measurements was assessed using intraclass correlation coefficient (ICC). The ICC of the measurements showed the values from 0.762 for the vertical change of the first molars to 0.989 for rotation measurements.

Table 1. Pretreatment parameters of the dental casts (independent t-test)

	cHerbst n=40		Class II elastics n=20		p value
	Mean	SD	Mean	SD	
RMR (°)	100.1	6.1	99.3	5.9	0.623
LMR (°)	100.3	6.2	99.6	6.0	0.660
Distance from the 3rd rugae perpendicular to the midsagittal line to:					
MR (mm)	11.2	2.2	11.4	1.4	0.754
ML (mm)	11.0	1.9	10.7	1.5	0.475
PR2 (mm)	4.4	1.9	4.6	1.5	0.877
PL2 (mm)	4.2	1.9	3.9	1.7	0.490
PR1 (mm)*	2.3	1.3	2.3	1.6	0.824
PL1 (mm)*	2.5	1.4	2.9	1.7	0.472
IMW (mm)	54.5	2.8	54.5	2.4	0.875
IPW2 (mm)	39.8	2.9	39.9	2.5	0.754
IPW1 (mm)	35.5	2.4	35.5	1.7	0.719

RMR, Rotation of the first molar to the midsagittal line right side ; LMR ,Rotation of the first molar to the midsagittal line left side ; Distances from the 3rd rugae perpendicular to the midsagittal line to: MR - the first molar right side ; ML, the first molar left side; PR2 ,the second premolar right side; PL2, the second premolar left side; PR1 , the first premolar right side; PL1, the first premolar left side; IMW, Intermolar width; IPW2,Inter-premolar width (2nd); IPW1, Inter-premolar width (1st). * The first premolars were situated above the 3rd rugae points.

Table 2. The mean movements of the posterior teeth in the groups (independent t-test)

	cHerbst n=80		Class II elastics n=40		Dif. Mean	95% confidence interval		p value
	Mean	SD	Mean	SD		upper	lower	
RM (°)	13.8	5.0	4.2	5.5	9.6	7.5	11.7	0.000
Antero-posterior changes								
AM (mm)	3.2	1.2	-0.3	1.5	3.4	2.9	4.0	0.000
AP2 (mm)	1.8	0.8	-0.5	1.3	2.3	1.9	2.7	0.000
AP1 (mm)	1.5	0.7	-0.1	1.2	1.6	1.3	2.0	0.000
Expansion								
EM (mm)	1.0	0.7	0.5	0.8	0.6	0.3	0.9	0.001
EP2 (mm)	1.7	1.2	0.9	0.9	0.9	0.4	1.3	0.000
EP1 (mm)	1.3	0.9	0.7	0.9	0.6	0.2	1.0	0.002
Vertical changes								
VM (mm)	-0.3	1.0	0.3	1.1	-0.6	-1.0	-0.2	0.008
VP2 (mm)	0.9	0.6	0.3	0.9	0.7	0.4	1.0	0.000
VP1 (mm)	1.2	0.6	0.9	0.9	0.4	0.1	0.7	0.013

Positive values indicate distobuccal rotation, distalization, expansion and extrusion; negative values mean mesiobuccal rotation, mesialization contraction and intrusion. RM, Rotation of the first molar; AM, Antero-Posterior 1st molar; AP2, Antero-Posterior 2nd premolar; AP1, Antero-Posterior 1st premolar; EMR, Expansion 1st molar; EP2, Expansion 2nd premolar; EP1, Expansion 1st pre-molar; VMR, Vertical 1st molar; VP2 , Vertical 2nd premolar; VP1 Vertical 1st premolar

Table 3. Pearson's correlation coefficients for the movements of the upper first molars in the crown Herbst group (n = 80)

	Rotation	Anteroposte-rior movement
Rotation		0.533**
Anteroposterior movement	0.533**	
Transverse movements	0.295**	0.415**

**p<0.01

RESULTS

The comparison of the starting forms is presented in Table 1. There were no statistically significant differences among the dental cast measurements in the groups before treatment. The differences in the dental movements produced by the appliances are presented in Table 2. The Herbst appliance produced statistically significantly more distal rotation compared to Class II elastics (9.6°). It also produced the distal movement of the molars (mean 3.4 mm, 95% CI 2.9 to 4.0) and premolars compared to Class II elastics. The distal movement of the molars in the cHerbst group contained a rotational component. Table 3 shows moderate correlations of the distal movements with rotations and expansion. In contrast to the distal movements, the buccal movements of the molars were smaller than of the premolars in the cHerbst group. In the cHerbst group the upper molars on average intruded (-0.3 ± 1.0 mm) while the premolars in the cHerbst group and all posterior teeth in the Class II elastics group extruded.

DISCUSSION

As all the consecutive patients were included in the study it can be assumed that the study population is representing average Class II patients assigned to nonsurgical and non-extraction Class II treatment. The sample was analyzed by a postgraduate student who was not aware of the treatment methods or the objectives of the study prior to the measurements being completed.

In this study the ICC values were higher compared to the previous studies (18, 19). The higher values can be accounted for the superimposition technique used in this study, which was done manually in contrast to auto-fit in other studies (18, 19, 23, 24). An important advantage of this method is the use of freeware instead of the commercial software (18, 19, 23, 24).

The mean distal movement of the upper molars was 3.2 mm, which is very close to the findings reported for the cHerbst appliance (8) or the banded Herbst appliance (4). However, these comparisons should be done with caution because of differences in the reference points for measuring the position of the molars: mesial contact point or mesiobuccal cusp. Depending on the design of the Herbst appliance, the position of the points could be changed by distal rotation rather than bodily movement of the molars.

The narrow CI for distalization of the molars in the cHerbst group was somewhat surprising because the patients were representing a population with different growth potential. Our results suggested that the

initial force from the rods and sleeves was pushing the upper molars backwards to some limit, which was about 3 mm, and the rest of correction was achieved by skeletal correction or movement of the lower dentition. The observed 0.3 mm anterior movement of the upper molars in the Class II elastics group was in accordance with the cephalometric studies (11-13).

It is known that in Class II patients often the upper molars are mesially rotated, and derotation of the upper molars would help in correction of Class II (25) and provide about 2 mm of space in the upper arch per side. Our results clearly showed an association between rotation and anteroposterior movement of the molars (Table 3). In the cHerbst sample a slight extrusion of the premolars was recorded (Table 2). This could facilitate establishment of intercuspitation already during the functional phase. These findings suggested that the design of the crown Herbst appliance had a large advantage over other Herbst designs, because it was not attached to other constructions. Several studies (5, 16) have stressed the importance of stability of occlusion in preventing relapse after Class II correction.

In the present sample, expansion was recorded at the premolar region for both the cHerbst and Class II elastic groups. The relative constriction of the maxillary arch related to the mandibular arch in Class II malocclusions is a common finding (26). Thus, some expansion is needed to compensate for the sagittal correction. Hansen *et al.* (17) showed expansion of the dental arch up to 3 mm at the molar region and only 1.5 mm at the premolar region. In contrast, we observed about 1.5 mm of expansion per side for the premolars and 1.0 for the molars, which corresponds to Valant and Sinclair findings (9).

A clinically insignificant extrusion of the upper molars was recorded in the Class II elastics group, and that compares favourably with the other studies (11-13), who observed significant extrusion of the upper molars about 2 mm. In addition, a slight intrusion of the upper molars was recorded in the cHerbst group. It had been emphasised before that the high - pull headgear effect of the Herbst appliance prevents the mandibular plane rotation (10, 11).

The study has several limitations. First, the ages of the patients are different in the groups and the treatment lengths vary. However, it has been reported that the posterior upper arch length decreases only by about 0.5 mm between the ages 13 and 16 as a result of normal development (27). The rugae points used in this study have been reported to be stable at that age (18, 19, 24). The other limitations of this study are the lack of the post-treatment observation period and no information about the distal tipping of the molars.

On the other hand, a previous cephalometric study (8) has reported the short and long-term changes in the inclination of the upper first molar after Class II correction with the crown Herbst appliance.

CONCLUSIONS

The crown Herbst produces clinically more significant derotation and distalization of the maxillary

molars compared to Class II elastics;

In the crown Herbst group the premolars followed the molars distally;

The posterior teeth in both groups extruded, while in the cHerbst group the molars intruded.

CONFLICT OF INTEREST

The authors declare no conflict of interest.

REFERENCES

- Cassidy SE, Jackson SR, Turpin DL, Ramsay DS, Spiekerman C, Huang GJ. Classification and treatment of Class II subdivision malocclusions. *Am J Orthod Dentofacial Orthop* 2014;145:443-51.
- Pancherz H. Treatment of class II malocclusions by jumping the bite with the Herbst appliance. A cephalometric investigation. *Am J Orthod* 1979;6:423-42.
- Silva JF, Gerszewski C, Moresca RC, Correr GM, Flores-Mir C, Moro A. Retrospective study of clinical complications during orthodontic treatment with either a removable mandibular acrylic splint Herbst or with a cantilever Herbst. *Angle Orthod* 2015;85:64-71.
- Pancherz H. The mechanism of Class II correction in Herbst appliance treatment. A cephalometric investigation. *Am J Orthod* 1982;82:104-13.
- Pancherz H, Hansen K. Occlusal changes during and after Herbst treatment: A cephalometric investigation. *Eur J Orthod* 1986;8:215-28.
- Konik M, Pancherz H, Hansen K. The mechanism of Class II correction in late Herbst treatment. *Am J Orthod Dentofacial Orthop* 1997;112:87-91.
- Ruf S, Pancherz H. Herbst/multibracket appliance treatment of Class II division 1 malocclusions in early and late adulthood. a prospective cephalometric study of consecutively treated subjects. *Eur J Orthod* 2006;28:352-60.
- Jakobsone G, Latkauskiene D, McNamara JAJr. Mechanisms of Class II correction induced by the crown Herbst appliance as a single-phase Class II therapy: 1 year follow-up. *Prog Orthod* 2013;11:14-27.
- Valant JR, Sinclair PM. Treatment effects of the Herbst appliance. *Am J Orthod Dentofacial Orthop* 1989;95:138-47.
- Pancherz H, Anehus-Pancherz M. The headgear effect of the Herbst appliance: A cephalometric long-term study. *Am J Orthod Dentofacial Orthop* 1993;103:510-20.
- Nelson B, Hansen K, Hägg U. Class II correction in patients treated with class II elastics and with fixed functional appliances: a comparative study. *Am J Orthod Dentofacial Orthop* 2000;118:142-9.
- Meistrell MEJr., Cangialosi TJ, Lopez JE, Cabral-Angeles A. A cephalometric appraisal of nonextraction Begg treatment of Class II malocclusions. *Am J Orthod Dentofacial Orthop* 1986;90:286-95.
- Jones G, Buschang PH, Kim KB, Oliver DR. Class II non-extraction patients treated with the Forsus Fatigue Resistant Device versus intermaxillary elastics. *Angle Orthod* 2008;78:332-8.
- Jayachandran S, Wiltshire WA, Hayasaki SM, Pinheiro FH. Comparison of AdvanSync and intermaxillary elastics in the correction of Class II malocclusions: A retrospective clinical study. *Am J Orthod Dentofacial Orthop* 2016;150:979-88.
- Bock N, Ruf S. Post-treatment occlusal changes in Class II division 2 subjects treated with the Herbst appliance. *Eur J Orthod* 2008;30:606-13.
- Pancherz H, Bjerklind K, Lindskog-Stokland B, Hansen K. Thirty-two-year follow-up study of Herbst therapy: a biometric dental cast analysis. *Am J Orthod Dentofacial Orthop* 2014;145:15-27.
- Hansen K, Iemamneisuk P, Pancherz H. Long-term effects of the Herbst appliance on the dental arches and arch relationships: a biometric study. *Br J Orthod* 1995;22:123-34.
- Jang I, Tanaka M, Koga Y, Iijima S, Yozgatian JH, Cha BK, et.al. A novel method for the assessment of three-dimensional tooth movement during orthodontic treatment. *Angle Orthod* 2009;79:447-53.
- Choi JI, Cha BK, Jost-Brinkmann PG, Choi DS, Jang IS. Validity of palatal superimposition of 3-dimensional digital models in cases treated with rapid maxillary expansion and maxillary protraction headgear. *Kor J Orthod* 2012;42:235-41.
- An K, Jang I, Choi DS, Jost-Brinkmann PG, Cha BK. Identification of a stable reference area for superimposing mandibular digital models. *J Orofac Orthop* 2015;76:508-19.
- Latkauskiene D, Jakobsone G, McNamara JA. A prospective study on the clinical effectiveness of the stainless steel crown Herbst appliance. *Prog Orthod* 2012;13:100-8.
- Andrews LF. The six keys to normal occlusion. *Am J Orthod* 1972;62:296-309.
- Cho MJ, Choi JH, Lee SP, Baek SH. Three-dimensional analysis of the tooth movement and arch dimension changes in Class I malocclusions treated with first premolar extractions: A guideline for virtual treatment planning. *Am J Orthod Dentofacial Orthop* 2010;138:747-57.
- Chen G, Chen S, Zhang XY, Jiang RP, Liu Y, Shi FH, et.al. Stable region for maxillary dental cast superimposition in adults, studied with the aid of stable miniscrews. *Orthod Craniofac Res* 2011;14:70-9.
- Liu D, Melsen B. Reappraisal of Class II molar relationships diagnosed from the lingual side. *Clin Orthod Research* 2001;4:97-104.
- Lombardo L, Setti S, Molinari C, Siciliani G. Intra-arch widths: a meta-analysis. *Int Orthod* 2013;11:177-92.
- Thilander B. Dentoalveolar development in subjects with normal occlusion. A longitudinal study between the ages of 5 and 31 years. *Eur J Orthod* 2009;31:109-20.

Received: 04 08 2017

Accepted for publishing: 20 09 2018

Maxillary Central Incisor Root Resorption due to Canine Impaction after Trauma. Is the Canine Substitution for Maxillary Incisors a suitable Treatment Option?

Two Case Reports

*Cinzia Maspero**, *Andrea Fama**, *Guido Galbiati**, *Lucia Giannini**, *Laima Kairyte**,
*Luca Bartorelli**, *Marco Farronato**

SUMMARY

Objective. Canine impaction is a dental anomaly involving intraosseous displacement of the unerupted tooth. This situation is of significant importance causing orthodontic, surgical and interceptive problems. Trauma in the incisor area is a possible cause of the displacement of the tooth bud of the permanent canine resulting in the deviated eruption path. The aim of this article is to present two clinical cases with diagnosis of maxillary canine displacement and impaction in the incisor region after a traumatic injury during childhood, discussing treatment possibilities and outcomes achieved after orthodontic treatment.

Materials and methods. In this article ectopic maxillary canines migration in the central incisor area after a traumatic injury to the anterior upper teeth are described. The path of eruption of the canine can cause severe central incisor root resorption. Treatment strategy established for the case reports described involves orthodontic space opening, extraction of the central incisor, uncovering the impacted canine and orthodontic traction of the tooth in place of central incisor. Modification of crown morphology and color were essential to obtain an aesthetic and function outcome.

Results. The patients finished treatment with normal and stable occlusion, an adequate width of attached gingiva and good aesthetic results.

Conclusion. Authors suggest that might have been a possible connection between the trauma of primary dentition causing the displacement of the tooth bud of permanent canine and the deviated path of eruption. For the growing patients with a combination of dental trauma and ectopic eruption, maxillary canine to replace a central incisor was a viable option, offering excellent aesthetic results without recourse to prosthetic replacement.

Key words: impacted maxillary canines, root resorption, ectopic eruption.

INTRODUCTION

Canine impaction is a dental anomaly involving intraosseous displacement of the unerupted tooth. This situation is of significant importance causing orthodontic, surgical and interceptive problems.

The permanent central incisor is considered one of the most important teeth in terms of aesthetics while the position of the permanent maxillary canine

at the angle of the dental arch is important both in maintaining the symmetry, the harmony of occlusal relationship and from the functional point of view.

The maxillary canine is the second most frequently impacted tooth, with a prevalence ranging between 1% and 2% (1).

The aesthetic and functional importance of canines requires an early diagnosis in order to recognize tooth displacement and to predict the resulting failure in eruption. For this reason, eruption process should be monitored in order to identify the etiological factors that lead to impaction of the maxillary canines (2). The process causing the deviation of the eruption path seems to be related to the lack of guidance

*Department of Orthodontics, University of Milan, Fondazione IRCCS Ca' Granda, Ospedale Maggiore Policlinico, Milano, Italy

Address correspondence to Giampietro Farronato, Department of Orthodontics, University of Milan, Fondazione IRCCS Ca' Granda, Ospedale Maggiore Policlinico, via Francesco Sforza 35, 20122 Milano (Mi), Italy.
E-mail address: laimakairyte@gmail.com