

Pleomorphic adenoma of buccal mucosa: a case report and review of the literature

Ernani Canuto Figueirêdo Júnior¹, Isabella Jardelino Dias¹, Pollianna Muniz Alves², Cassiano Francisco Weege Nonaka², Daliana Queiroga de Castro Gomes², Jozinete Vieira Pereira²

SUMMARY

Background. Salivary gland neoplasms are rare, accounting for 3% to 5% of all head and neck tumors, and involvement of the minor salivary glands is uncommon. Pleomorphic adenoma (PA) is the most common benign neoplasm, which mainly affects the parotid gland. However, involvement of the cheek mucosa is very rare.

Objective. This study reports a case of PA in the cheek mucosa. In addition, the etiopathogenesis, clinical and morphological features and differential diagnoses of PA are discussed, emphasizing the importance of knowledge about the characteristics of this tumor for a correct diagnosis.

Case report. A 50-year-old woman presented with a nodular lesion of endophytic growth in the left cheek mucosa. The lesion was small and well-delimited and had a normal mucosa color and intact surface. An excisional biopsy of the lesion was performed, and the diagnosis was PA.

Conclusion. Although the occurrence of PA in the minor salivary glands of the cheek mucosa is uncommon, the early establishment of a correct diagnosis and initiation of appropriate treatment are important because they permit effective management of the condition and improvement in the prognosis of patients.

Key words: salivary gland neoplasms, salivary glands, minor; adenoma, pleomorphic; diagnosis; therapy.

INTRODUCTION

Salivary gland neoplasms are a heterogeneous group of tumors that exhibit variable clinical, histological, and immunohistochemical features (1). These tumors are rare, accounting for only 3 to 5% of all neoplastic processes that occur in the jaws (2). Of these, 64.9% to 67.5% are benign neoplasms (3, 4). Minor salivary gland neoplasms, such as those occurring in the cheek mucosa, lip and tongue, are even rarer (3-5).

Pleomorphic adenoma (PA) is the most common benign salivary gland neoplasm, accounting for 33.2% to 68.4% of all cases (4, 5). This tumor mainly occurs in the parotid glands, while the cheek mucosa, lip and tongue are less affected sites (2, 4-6). PA is

more common in females between 40 and 50 years of age (4-7). Clinically, PA presents as a slow-growing, asymptomatic lesion of firm consistency and variable diameters (8, 9) but well delimited. Intraoral PA is generally located in the submucosa and exhibits a firm or rubbery consistency. The mucosal lining remains intact, although ulcerations are observed in some cases (8, 10).

At these intraoral sites, including the cheek mucosa, lip and tongue which are susceptible to trauma, PA can clinically mimic other reactive processes of the salivary glands, as well as non-neoplastic proliferative processes. Within this context, we report a case of PA in the cheek mucosa and discuss the etiopathogenesis, clinical and morphological findings and differential diagnoses of PA which help make the correct diagnosis.

CASE REPORT

A 50-year-old white woman, a farmer, sought the Dental Teaching Clinic of the State

¹Postgraduate Program in Dentistry, State University of Paraíba, Campina Grande, PB, Brazil

²Department of Dentistry, State University of Paraíba, Campina Grande, PB, Brazil

Address correspondence to Ernani Canuto Figueirêdo Júnior, State University of Paraíba, Postgraduate Program in Dentistry, Rua das Baraúnas 351, Bairro Universitário, Campina Grande, PB, 58429-500, Brazil.

E-mail address: ernanicfjunior@outlook.com

University of Paraíba complaining of a small painless lump that had appeared on the cheek 4 years ago. During anamnesis, the patient reported to be an ex-smoker and non-drinker, as well as the absence of any comorbidity. Extraoral physical examination revealed no lymph node involvement. Intraoral examination detected a mobile, fibrous, endophytic nodule in the left cheek mucosa measuring approximately 0.5 cm in diameter. The nodule was well-delimited, had a regular contour, a smooth surface and a normal mucosa color and was asymptomatic to touch (Figure 1).

Based on the clinical data, the diagnostic hypotheses were fibroma, lipoma or inflammatory fibrous hyperplasia since the region was susceptible to trauma. After verification of preoperative examinations, an excisional biopsy was performed and the specimen was submitted to histopathological analysis. Microscopic analysis revealed the presence of a partially encapsulated benign neoplasm of glandular origin, which was characterized by the proliferation of epithelial and myoepithelial cells in a predominantly duct-like pattern. These duct-like structures were lined internally with epithelial cells and externally with round myoepithelial cells containing central round nuclei. Eosinophilic material compatible with mucin was observed inside the duct-like structures. Cell proliferation in nest-like arrangements was sometimes seen in the lesion. The cells had a round shape and contained oval central, sometime eccentric, nuclei with a plasmacytoid appearance (Figures 2-5). Based on the histopathological findings, the final diagnosis was PA.

One year after surgical resection of the lesion, the patient continues under follow-up and shows no signs of recurrence.

The authors obtained written informed consent from the patient concerned to publication of the present material in compliance with the ethical guidelines.

DISCUSSION

Pleomorphic adenoma occurs mainly in the major salivary glands (4, 7, 9-13) and is uncommon in the minor salivary glands (2, 7, 9-14). Thus, the present case of PA in the minor salivary glands of the cheek mucosa corroborates literature data showing a relatively low prevalence at this site (2, 14) compared to predilection sites such as the palate (64%) and other less commonly affected sites such as the upper lip (13%) (6).

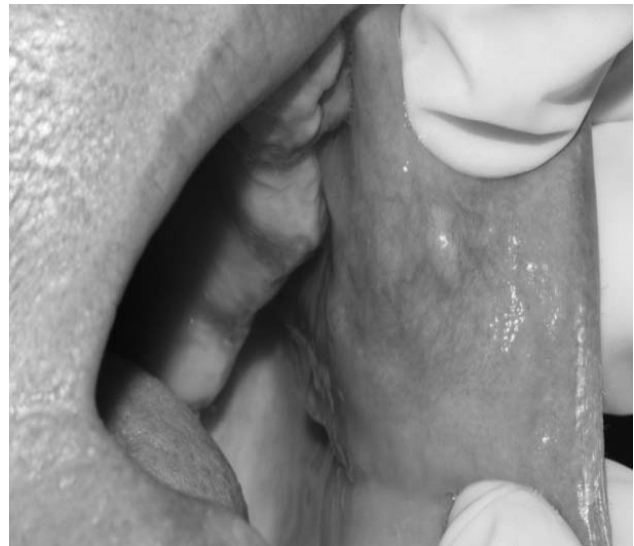

Fig 1. Intraoral view showing a small nodule on the cheek mucosa, which was firm to palpation

Regarding the epidemiological aspects of PA, the sex and age of the present case agree with the literature showing that PA in the minor salivary glands most commonly affects women in their fourth and fifth decade of life, with a mean age of 45-50 years (4-6).

The clinical features of the lesion were consistent with those reported in the literature for cases of intraoral PA, with the observation of an asymptomatic, slow-growing nodular lesion of firm consistency covered with normal mucosa and the absence of ulcerations (8-10). An interesting finding of the present case was the size of the lesion. In contrast to the tendency for growth and size variation of PA (9, 10), in our case, the tumor had a small size considering the long interval between the time the patient had noticed the lesion and intervention and establishment of the histopathological diagnosis.

The anatomopathological findings are consistent with the microscopic characteristics of PA, particularly the presence of epithelial components arranged in duct-like structures and their association with myoepithelial cells in a stroma exhibiting variable patterns such as mucoid, myxoid, cartilaginous, or hyaline (8, 15).

The variety of histological patterns observed in the tumor studied here corroborates the variable pattern commonly found in salivary gland neoplasms. This histomorphological diversity is attributed to the histogenesis of these tumors, which is related to the cell type (16, 17). The histogenesis of PA is associated with reserve cells of the intercalated duct. In this respect, the capacity of reserve cells to differentiate into

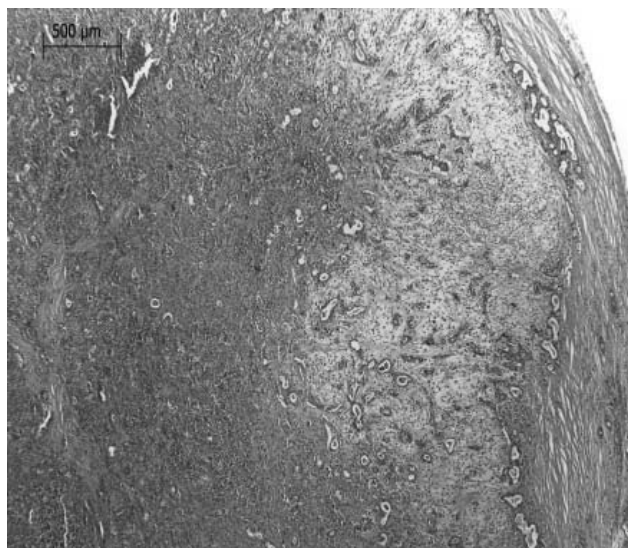


Fig 2. Photomicrograph showing the lesion which was partially surrounded by a capsule of dense fibrous connective tissue. Note the varied stroma with a more myxoid area (hematoxylin-eosin, 40×)

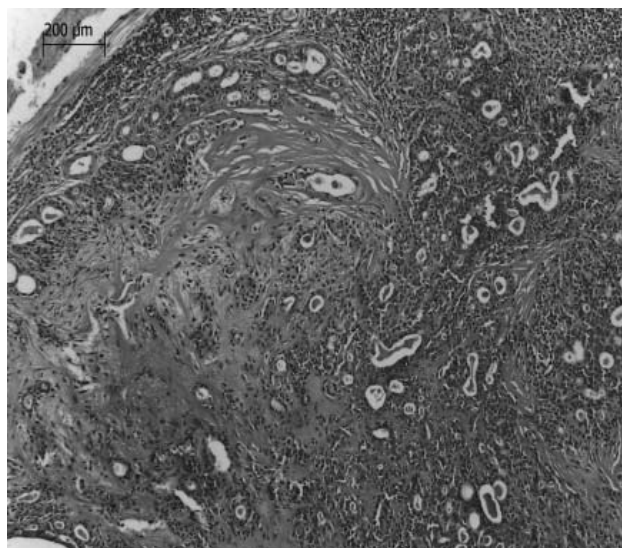


Fig 3. Photomicrograph showing the parenchyma rich in duct-like structures amidst more hyaline stroma (hematoxylin-eosin, 100×)

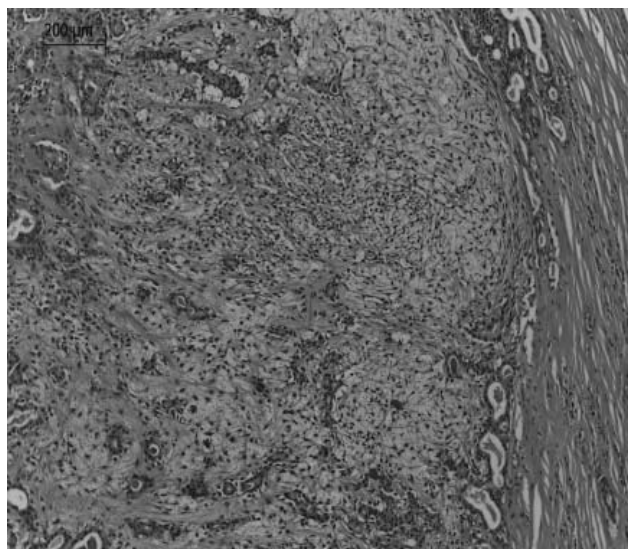


Fig 4. Photomicrograph, at higher magnification, showing varied stroma intermingled with numerous duct-like structures (hematoxylin-eosin, 100×)

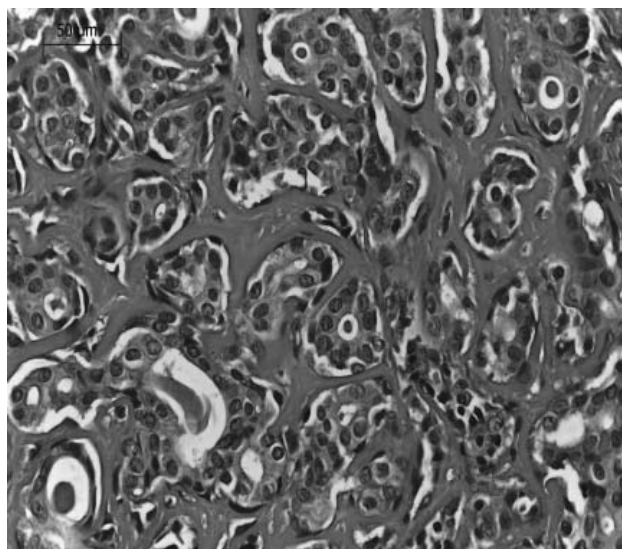


Fig 5. Photomicrograph, at higher magnification, showing the duct-like structures and small nests of plasmacytoid cells (hematoxylin-eosin, 400×)

different subtypes explains the morphological heterogeneity found in salivary gland neoplasms, which can even vary in different areas of the same tumor (17).

In summary, the anatomopathological findings were conclusive to establish the definitive diagnosis of PA. This diagnosis was different from the diagnostic hypotheses proposed during initial clinical examination of the patient since some of these diagnostic hypotheses were mainly based on the clinical data of the lesion and its anatomical location along the occlusion line, a site constantly exposed to traumatic injuries caused by mastication or other local irritants. Thus, these data may point to the diagnosis of inflammatory and reactive lesions

(18, 19). However, in addition to inflammatory and reactive lesions, other soft tissue neoplasms may also be included as diagnostic hypotheses (18), such as neurilemoma (8, 10), lipoma, neurofibroma (8, 14) and minor salivary gland neoplasms (8-10). Although not initially considered a diagnostic hypothesis, minor salivary gland neoplasm was the definitive diagnosis.

Although the etiopathogenesis of PA is associated with the proto-oncogene *PLAG1* (20-22), which is activated due to chromosomal aberrations that result in the fusion with genes such as *CTNNB1* and *LIFR* (20, 23), the occurrence of this neoplasm at extraoral sites affected by previous mechanical traumas has been reported (24, 25). In view of these

reports and the diagnosis of PA at an intraoral site exposed to constant traumatic injuries in the present case, one may question and discuss the possible role of this agent in the development of this neoplasm. From this perspective, these findings may induce a discussion about a possible relationship between the occurrence or role of mechanical traumas and the development of PA, questioning whether the development of this neoplasm in mechanically injured areas is a mere association or whether the development of PA is influenced by secondary events resulting from mechanical injuries (24).

Finally, although formulating diagnostic hypotheses is a crucial step, the importance of establishing a conclusive diagnosis is reiterated. Although the overall appearance of a lesion can suggest a variable number of hypotheses, the conclusive result is established only by anatomopathological examination. For this purpose, surgical excision respecting a margin of surrounding normal tissue with preservation of the capsule is the recommended treatment for

PA (8-10, 14, 15, 26-28). The early diagnosis of PA is important since, despite the rare occurrence of this tumor (26, 29, 30), secondary malignant transformation to carcinoma ex pleomorphic adenoma is possible (7, 11, 28-30).

CONCLUSION

The present results emphasize the importance of establishing a correct diagnosis and treatment of the alterations that can affect the oral and maxillofacial regions, as well as of the follow-up of cases, particularly those diagnosed as PA. Obtaining a diagnosis as early as possible is essential since it permits effective management of the lesion and a better prognosis. In this regard, PA requires long-term follow-up for the investigation of possible recurrences and/or evolution of the case.

CONFLICT OF INTEREST

The authors state no conflict of interest.

REFERENCES

- Cavalcante RB, Nonaka CFW, Rabenhorst SHB, Miguel MCC, Pinto LP, Batista de Souza L. Pleomorphic adenoma and adenoid cystic carcinoma of salivary glands: E-cadherin immunoeexpression and analysis of the CDH1 -160C/A polymorphism. *Arch Oral Biol* 2017; 73:48–54.
- Khandekar VS, Dive A, Munde P, Wankhede ND. Pleomorphic adenoma of the buccal salivary gland. *J Oral Maxillofac Pathol* 2015; 19:111-116
- Ito FA, Ito K, Vargas PA, Almeida OP, Lopes MA (2005) Salivary gland tumors in a Brazilian population: a retrospective study of 496 cases. *Int J Oral Maxillofac Surg* 2005; 34:533-536.
- Jones AV, Craig GT, Speight PM, Franklin CD. The range and demographics of salivary gland tumors diagnosed in a UK population. *Oral Oncol* 2008; 44:407–417.
- Pires FR, Pringle GA, Paes de Almeida O, Chen S. Intra-oral minor salivary gland tumors: A clinicopathological study of 546 cases. *Oral Oncol* 2007; 43:463-470.
- Abrahão AC, Santos Netto JN, Pires FR, Santos TC, Cabral MG. Clinicopathological characteristics of tumours of the intraoral minor salivary glands in 170 Brazilian patients. *Br J Oral Maxillofac Surg* 2016; 54:30-34.
- Kiciński K, Mikaszewski B, Stankiewicz C. Risk factors for recurrence of pleomorphic adenoma. *Otolaryngol Pol* 2016; 70:1-7.
- Rahnama M, Orzędała-Koszel U, Czupkałło L, Lobacz M. Pleomorphic adenoma of the palate: a case report and review of the literature. *Contemp Oncol (Pozn)* 2013;17: 103–106.
- Singh AK, Kumar N, Sharma P, Singh S. Pleomorphic adenoma involving minor salivary glands of upper lip: A rare phenomenon. *J Cancer Res Ther* 2015; 11:1025.
- Qureshi MY, Khan TA, Dhurjati VN, Gaddikeri K, Khany MZ. Pleomorphic adenoma in retromolar area: a very rare case report and review of literature. *J Clin Diagn Res* 2016;10:ZD03- ZD05.
- Vento SI, Numminen J, Kinnunen I, Rautiainen M, Tarkkanen J, Hagström J, et al. Pleomorphic adenoma in the nasal cavity: a clinicopathological study of ten cases in Finland. *Eur Arch Otorhinolaryngol* 2016;273:3741-3745.
- Wierzchowska M, Bodnar M, Burduk PK, Kaźmierczak W, Marszałek A. Rare benign pleomorphic adenoma of the nose: short study and literature review. *Wideochir Inne Tech Maloinwazyjne* 2015; 10:332–336.
- Yang L, Tan L, Lau Q, Jayalath R. Rare Primary Pleomorphic Adenoma in Posterior Fossa. *World Neurosurg* 2016; 93:e5-e8.
- Velupula N, Annam SR, Palapati SR, Kumar R, Kumar A. Pleomorphic adenoma of cheek masquerading as fibrolipoma - Case report with review. *J Clin Diagn Res* 2015;9:ZD13-ZD15.
- Hakeem AH, Hazarika B, Pradhan SA, Kannan R. Primary pleomorphic adenoma of minor salivary gland in the parapharyngeal space. *World J Surg Oncol* 2009; 7:1-4.
- Akrish S, Peled M, Ben-Izhak O, Nagler RM. Malignant salivary gland tumors and cyclo-oxygenase-2: a histopathological and immunohistochemical analysis with implications on histogenesis. *Oral Oncol* 2009; 45:1044-1050.
- Dwivedi N, Agarwal A, Raj V, Chandra S. Histogenesis of salivary gland neoplasms. *Indian J Cancer* 2013; 50:361-366.
- Kadeh H, Derakhshanfar G, Saravani S. Comparative Study of Mast Cell Count in Oral Reactive Lesions and Its Association with Inflammation. *Turk Patoloji Derg* 2016;32:22-26.
- Rivera C, Droguett D, Arenas-Márquez MJ. Oral mucosal lesions in a Chilean elderly population: A retrospective study with a systematic review from thirteen countries. *J Clin Exp Dent* 2017; 9: e276-e283.
- De Brito BS, Gaspar NG, Egal ES, Sanchez-Romero C, Martins AS, Tincani AJ, et al. PLAG1 expression is maintained in recurrent pleomorphic adenoma. *Virchows Arch* 2016;469:477-481.
- Jakobiec FA, Stagner AM, Eagle Júnior RC, Lally SE, Krane JF. Unusual pleomorphic adenoma of the lacrimal gland: immunohistochemical demonstration of PLAG1 and HMG A2 oncoproteins. *Surv Ophthalmol* 2017; 62:219-226.

22. Wang Y, Shang W, Lei X, Shen S, Zhang H, Wang Z, et al. Opposing functions of PLAG1 in pleomorphic adenoma: a microarray analysis of PLAG1 transgenic mice. *Biotechnol Lett* 2013;35:1377-1385.
23. Yin LX, Ha PK. Genetic alterations in salivary gland cancers. *Cancer* 2016;122:1822-1831
24. Hsu H. Posttraumatic benign pleomorphic adenoma of the lacrimal gland. *Ophthalmologica* 2001;215:235-237.
25. Požgain Z, Dulić G, Kristek J, Rajc J, Bogović S, Rimac M, et al. Giant primary pleomorphic adenoma of the lung presenting as a post-traumatic pulmonary hematoma: a case report. *J Cardiothorac Surg* 2016;11:1-4.
26. Goyal P, Sehgal S, Ghosh S, Agrawal D, Singh S. Rare carcinoma ex pleomorphic adenoma of buccal mucosa: case report and review of literature. *Rare Tumors* 2016; 8:11-13.
27. Laturiya R, Kasim JS, Jankar AS, Mohiuddin SA. Pleomorphic adenoma of minor salivary gland arising de novo in the parapharyngeal space - a rare case report. *J Clin Diagn Res* 2016;10: ZD01–ZD03.
28. Misra S, Bhandari A, Misra N, Gogri P, Mahajan S. Pleomorphic adenoma of a deep orbital ectopic lacrimal gland. *Orbit* 2016;35:295-297.
29. Kini Y, Desai C, Mahindra U, Kalburgue J. Rare carcinoma ex pleomorphic adenoma of the buccal minor salivary gland causing a therapeutic dilemma. *Contemp Clin Dent* 2012; 3:209–211.
30. Mariano FV, Egal ES, Pramio D, Fidalgo F, Sara É, Costa AF, et al. Evaluation of a subset of tumor suppressor gene for copy number and epigenetic changes in pleomorphic adenoma and carcinoma ex-pleomorphic adenoma carcinogenesis. *Oral Surg Oral Med Oral Pathol Oral Radiol* 2016;122: 322-331.

Received: 16 06 2018
Accepted for publishing: 25 09 2020